



## **ESMS POSITION DOCUMENT ON THE USE OF MOHS MICROGRAPHIC SURGERY AND OTHER MICROGRAPHIC SURGERY TECHNIQUES IN EUROPE**

### **Authors:**

John Paoli<sup>1</sup>, Olivier Cogrel<sup>2</sup>, Simone van der Geer<sup>3</sup>, Gertrud Krekels<sup>3</sup>, John de Leeuw<sup>4</sup>, Matthias Moehrle<sup>5,6</sup>, Judith Ostertag<sup>3</sup>, Luis Ríos Buceta<sup>7</sup>, Nisith Sheth<sup>8</sup>, Severin Läuchli<sup>9</sup>

### **Affiliations:**

1. Department of Dermatology and Venereology, Institute of Clinical Sciences, Sahlgrenska Academy, University of Gothenburg, Gothenburg, Sweden
2. Dermatology Department, Centre Hospitalier Universitaire de Bordeaux, Bordeaux University, Bordeaux, France
3. Mohs Academy (MohsA), Eindhoven, The Netherlands
4. Mohs European Consulting, 's-Gravendeel, The Netherlands
5. Praxisklinik Tübingen - Haut und Venen, Tübingen, Germany
6. Department of Dermatology, University Hospital, Tübingen, Germany
7. Department of Dermatology, Ramon y Cajal Hospital, Madrid, Spain
8. Department of Dermatologic Surgery and Laser Unit, Guy's and St. Thomas' Hospitals, London, UK.
9. Department of Dermatology, University Hospital Zurich, Switzerland

# **ESMS POSITION DOCUMENT ON THE USE OF MOHS MICROGRAPHIC SURGERY AND OTHER MICROGRAPHIC SURGERY TECHNIQUES IN EUROPE**

## **Table of contents**

1. Introduction .....	3
2. History of Mohs micrographic surgery and the ESMS.....	4
3. Mohs micrographic surgery - technique and requirements .....	6
4. Lab technique .....	8
5. Other methods of micrographic surgery .....	12
6. Indications and limitations for Mohs micrographic surgery and other micrographic surgery techniques .....	17
7. Adjuvant therapy in MMS.....	22
8. Patient Perspective .....	25
9. Current use in Europe, ESMS certification .....	27
10. The future of MMS and MS .....	28
11. References .....	29
12. Appendix - H&E staining procedure. ....	36

## 1. Introduction

Since its first description by Frederic Mohs in 1932, Mohs micrographic surgery (MMS) has undergone many changes in techniques and scope of applications. Today, it is very widely used in the USA as a standard procedure for many cases of skin cancer treatment. In Europe, the dissemination of the technique started in the 1970s and 1980s after some European dermatosurgeons learned the technique in the USA and started to implement it in their countries. New variations of the technique were introduced successfully in many centres.

There is widespread agreement that micrographic surgery (MS) and, in particular, classic MMS results in the highest cure rates and best aesthetic outcomes for many types of skin cancer. However, as it is a more labour-intensive procedure, it cannot be used for all skin cancers. It should be reserved for tumours with high recurrence rates, such as infiltrative, large or ill-delineated tumours; recurrent tumours or in situations where patient factors (such as immunosuppression) would otherwise lead to high recurrence rates. Furthermore, it has been shown that MMS is a tissue-sparing technique that leads to smaller excision defects. Therefore, it is particularly useful in locations where larger defects would lead to functional or aesthetic impairment.

There is a large body of literature supporting the use of MMS in situations requiring complete margin control and all the relevant guidelines and appropriate use criteria (e.g. the AUC published by the American Academy of Dermatology<sup>1</sup>) have taken this into account. However, no guidelines have been published so far looking at the technique from a European perspective. Whilst many criteria for appropriate use are the same all over the world, there are some distinct features that influence the use in Europe. Due to long-held traditions, different workflows have been developed in some countries, such as Germany in which they more frequently use paraffin sections for complete margin control. Later introduction and limited availability of MMS and MS techniques has led to more restrictive indications in some instances.

This document has been conceived as a position document by leading European experts on MMS and MS who are members of the European Society for Micrographic Surgery (ESMS), describing details of the MMS technique, variations of MS and their indications from a European perspective.

## 2. History of Mohs micrographic surgery and the ESMS

The MMS technique was introduced in 1932 when the American surgeon Frederic E. Mohs (deceased July 2, 2002) was a medical student and worked under the direction of geneticist Michael Guyer in the zoology department of the University of Wisconsin. Guyer injected colloidal platinum into rat tumours and found that it prevented tumour growth. Mohs decided to test other chemicals this way and observed their effects at a microscopic level. Thus, he discovered that the injection of a 20% zinc chloride solution produced a fixation of the tissue while maintaining its architecture intact. This in situ fixation allowed for histopathological control of the tissue. Later, he realised that horizontal sections were more appropriate than vertical sections since they allowed him to observe the entire deep edge of the specimen. He was also able to make a map by recording the place from which each of the samples came and thus only having to re-intervene on the affected areas with remaining tumour cells. Thus, the essence of MMS was discovered, i.e. staged excisions using horizontal sections, subsequent elaboration of a map and complete histopathological control of the removed tissue margins.

Initially, the technique was called chemosurgery because it was thought that fixation with zinc chloride paste was more important than microscopic control. It was difficult to find a suitable vehicle for Zinc chloride but finally F. Mohs developed a formula with stybonite and sanguinaria canadensis that allowed a homogenous diffusion of Zinc chloride. The final formula was: stybonite 40 g, sanguinaria canadensis 10 g and saturated zinc chloride 34.5 ml.<sup>2</sup> In 1936, the treatment of tumours began in patients with this technique.<sup>3</sup> The application of the paste was very painful and required a minimum of 24 hours between each stage. The reconstruction after the last stage was performed after a few weeks. In 1941, Mohs presented the very favourable results after the treatment of 440 patients with the fixation method with zinc chloride paste.<sup>4</sup> The 5-year cure rates with this technique were 96.6% in basal cell carcinoma (BCC) and 94.8% in cutaneous squamous cell carcinoma (cSCC).<sup>5</sup>

For the treatment of tumours located on the eyelids, Mohs observed that he could not use the paste because of the risk of causing corneal ulcers. In these cases, he used the technique in fresco without the use of the fixative paste.<sup>6</sup> In 1966, Ted Tromovitch began to use the in fresco technique in tumours with other locations. He published his results in 1974 showing similar cure rates to that obtained with chemosurgery.<sup>7</sup> From that moment, the use of the zinc chloride paste was reduced drastically since the fresh tissue method was more comfortable for the patient and offered the advantage of an immediate reconstruction of the defect. This fact was of great importance since, until then, the great majority of the cases were allowed to heal by secondary intention which didn't always produce good aesthetic results. In 1983, Zitelli published an article that clearly specified the anatomical areas where a good aesthetic result can be expected after secondary intention healing.<sup>8</sup>

In 1966, Perry Robins created the first one-year course for specialization in MMS, while also founding the International Society of Dermatological Surgery (ISDS) and the Journal of Dermatologic Surgery and Oncology tirelessly working to promote the technique worldwide. The American College of Mohs Surgery (ACMS) was founded in 1967 by Mohs, who also served as the first President of the college that now has more than 1200 members.

Robins, based in New York, also taught the first European dermatologists to develop the MMS technique. The German dermatologist Günter Burg was the pioneer in this experience. After learning the technique with Robins, he also spent some time with Mohs before starting to use the fixed tissue technique at his hospital in Munich in 1972. Subsequently, Birger Konz developed the Munich technique (see below) in 1977 and spread the use of this MS technique through Germany. In 1978, the first meeting of the ISDS took place in Marrakech, generating a meeting point between European and American dermatologists. Two years after this encounter, Dr. António Picoto, who had been taught by Robins, established his MMS unit at the Center for Dermatology Medical Surgery in Lisbon where many European dermatologists would later be trained. Shortly afterwards, in Spain, Francisco

Camacho, Alex Camps-Fresneda and Julián Conejo-Mir began to perform MMS in Seville and Barcelona. In 1983, Bo Stenquist started the first MMS centre in Scandinavia in Gothenburg, Sweden. In the mid-1980s, the technique spread to the UK with pioneers such as Elizabeth Crouch, William Bowers, Richard Motley, Mike Dahl, Neil Walker and Christopher Zachary. In 1988, Helmut Breuninger from Tübingen, Germany developed the MS technique called Tübinger Torte which gained a great acceptance in Germany.

On April 6-7, 1990, the founding of the ESMS took place in Estoril, Portugal. The founders were: António Picoto (President), Celeste Galvão Brito, José Manuel Labareda, Fernando Ribas and Paulo Santos from Portugal; Francisco Camacho, Alex Camps-Fresneda, Julián Conejo-Mir and Pablo Umbert from Spain; Helmut Breuninger, Birger Konz and Günter Burg from Germany; Patrick Dierick, Arlette de Coninck and Diane Roseeuw from Belgium; Olle Larkö and Bo Stenquist from Sweden; Richard Motley and Neil Walker from the UK; Leonardo Marini and Giorgio Landi from Italy; Alex Ginzburg from Israel and Martino Neumann from the Netherlands. Since its creation, the ESMS has gone through periods of greater and lesser activity. Initially, annual meetings were held in conjunction with the ISDS meetings (Florence in 1990, Munich in 1991 and Paris in 1992) and, more recently, the meetings have been held during the European Academy of Dermatology and Venereology (EADV) congresses. The ESMS is a subspecialty society of the EADV, which now has more than 120 members from 23 different countries. The Executive Board members meet at least once per year and the society issues European certifications to Mohs and micrographic surgeons fulfilling the established requirements that can be consulted on the ESMS website ([www.esms-mohs.eu](http://www.esms-mohs.eu)). Courses and scientific meetings at the EADV congresses are also organised to spread knowledge about the techniques.

MMS and MS are currently practiced in many European countries. Although classic MMS is the most commonly practiced technique, other MS techniques are available and will be discussed further below. The choice of technique is often determined by the characteristics and historic traditions of the centre that performs them and/or by the characteristics of the tumour being treated.

### 3. Mohs micrographic surgery - technique and requirements

MMS is probably the most reliable conservative approach for the management of skin cancers.<sup>9</sup> Prior to the advent of MMS, most skin cancer treatments relied on the operator's visual assessment of the tumour and its margins. MMS is more precise and relies on the principal of staged excisions and microscopically mapping of the peripheral and deep margins to trace out the tumour. MMS aims to preserve as much healthy tissue as possible, whilst insuring all tumour and its roots are excised. This results in the highest cure rates and the best long-term cosmetic outcomes.<sup>10,11</sup> The technique does however rely on the tumour being histopathologically contiguous.

The pre-operative assessment must take into account both tumour and host factors. To be eligible for MMS, the patient must be suitable to undertake a procedure under local anaesthetic that may take place over several hours. Consideration must be taken of the patient's co-morbidities, medications (particularly anticoagulants and immunosuppressants) as well as their functional state and social support network to cope with the post-operative experience.

Reconstruction needs to be considered in advance. Where local anaesthetic reconstruction is not possible by the MMS surgeon (e.g. extensive reconstruction or specialist site-specific repairs) or because of patient or physician choice (even if the reconstruction is within the capabilities of the MMS surgeon), it may be appropriate to enlist the help of surgical colleagues working closely with the MMS surgeon to undertake surgical repairs perhaps under general anaesthesia.

The risks, benefits and alternatives to MMS should be discussed with the patient. Ideally, the tumour must be histopathologically proven with a biopsy prior to the date of MMS, though clinically obvious tumours may be amenable to vertical section verification on the day of MMS prior to the horizontal section stages.<sup>12</sup>

Following confirmation of informed consent, the clinical margins are defined and marked by the surgeon with a surgical marker. Local anaesthesia is infiltrated around the tumour site. The tumour is then debulked using a Volkman spoon, curette, surgical blade or combination of the above. Care must be taken to minimise damage to healthy tissue. The following three steps are then carried out:

#### ***Step I***

The tumour is excised with a 2-3 mm clinical margin drawn onto the skin with a surgical marker. The margin may be larger for very extensive or recurrent tumours, or those with a great risk of non-contiguous extension (e.g. lentigo maligna or sebaceous carcinoma). The tissue that will be removed is carefully oriented by cutting small notches crossing the drawn outline at noon, 3 o'clock, 6 o'clock and 9 o'clock making sure to leave marks in both the tissue layer to be removed and in the corresponding skin remaining on the patient. The excision is then made at a 45-degree incision angle following the demarcation to increase the chance of obtaining a more complete epidermal edge during step III below. However, there is evidence that a 90-degree incision angle may be just as effective particularly at sites of thin skin, e.g. periocular area.<sup>13</sup> The excised tissue should be removed as a single complete layer with no holes.

#### ***Step II***

Next, the tissue must be mapped and marked with ink to maintain orientation. Hand-drawn sketches of anatomic sites, pre-printed maps or digital photographs can be used to map out the relationship between the excised tissue and the surgical defect.

#### ***Step III***

The tissue is divided into pieces (sections) small enough to fit onto a cryostat block. The cut margins are inked so that any tumour can be accurately mapped. At least 2 colours are required per section, and at least 3 if there is no epidermal edge in the tissue excised. The tissue is laid flat on filter paper

with the epidermal edge marked on the paper. The sections are numbered on the filter paper and the map. The harvested tissue is then embedded in optimal cutting temperature (OCT) compound, frozen, sectioned and prepared according to the descriptions in the “Lab technique” section below.

Flattening the tissue in order to section the complete undersurface and the epidermal margin at the same time is critical for the complete en-face examination of the outer margin of a tissue specimen. Relaxing cuts on the surface of the tissue are useful for flattening thick specimens. MMS surgeons must be aware of how to flatten, freeze, cut and stain tissue in order to efficiently communicate and troubleshoot quality issues with their histotechnician or MMS lab technician (LT).

The LT prepares horizontal section slides for evaluation as described further below. The MMS surgeon then evaluates the slides to determine if the margins are involved. In member countries where the MMS surgeon is not permitted to report on the histopathology, a pathologist may report on the slides in conjunction with the surgeon. If tumour is present, the corresponding location on the map is marked. If the lateral margin is involved, an additional excision of tissue in the affected area is removed with an appropriate margin. If tumour is present in the deep margin, an incision is made along the inside of the defect’s edges and a thin strip of tissue is removed from the depth. If both the lateral and deep margins are involved, both areas should be included in the next excision. Step III is then repeated until the tumour is completely excised. The stages are repeated until the margins are considered clear and, finally, the reconstruction of the surgical defect can be performed.

If tumour is absent, but less than 100% of the margin and depth is seen, then further excision is made at and around the site of missing tissue and processed as per steps I-III. This ensures that 100% of the margin is seen. There is lack of consensus on what to do if only a small amount of tissue is missing.<sup>14</sup> The judgement needs to be made on a case-by-case basis taking into account site, tumour type, cosmetic and functional implications. A balance needs to be made between the importance of preserving tissue and minimising the chance of recurrence.

## **4. Lab technique**

As mentioned above, the MMS surgeon requires fresh frozen sections of the excised tissue to microscopically examine the possible involvement of the lateral and/or deep margins or the complete removal of the tumour. The frozen sections are prepared by a LT with special training to quickly produce high quality slides so that the subsequent stages of MMS and/or defect reconstruction can take place in an efficient manner.

The standard MMS lab procedure includes the following steps that always need to be followed in order to obtain frozen sections of fresh tissue specimens: a) preoperative preparation; b) registration; c) macroscopy; d) mapping and inking; e) embedding; f) microtomy; g) staining; h) quality control by microscopy and i) consultation with the MMS surgeon and pathologist. The most important moments in the process are the mapping and inking as well as the embedding of the specimen.

### ***A. Preoperative preparation***

Before starting the MMS procedure, the LT will review the list of scheduled patients undergoing surgery that day in order to prepare and label the slides which will be used during the procedure. The exact number of slides needed will depend on the size of the specimens, the quality of the slides and the number of sections required by the surgeon. Each slide should be labelled with the case number, the patient's name or initials, date of birth, specimen piece number/letter and the level number. Chucks for the cryostat should also be prepared. In a standard case, two chucks per case are required before starting the procedure. Lastly, the cryostat should be turned on and the temperature set between -25°C and -30°C.

### ***B. Registration***

When the LT receives the specimen obtained after the first MMS stage as well as every consecutive tissue specimen after that, the patient information on the MMS lab form should be checked to make sure that the specimen is from the correct patient. If this is 100% correct, the first specimen is given a case number which the LT will also use for all consecutive specimens for that particular patient and tumour during the rest of the MMS procedure. Besides registering the case number, the LT also writes down the name and date of birth of the patient and how many pieces of the specimen exist on the MMS lab form.

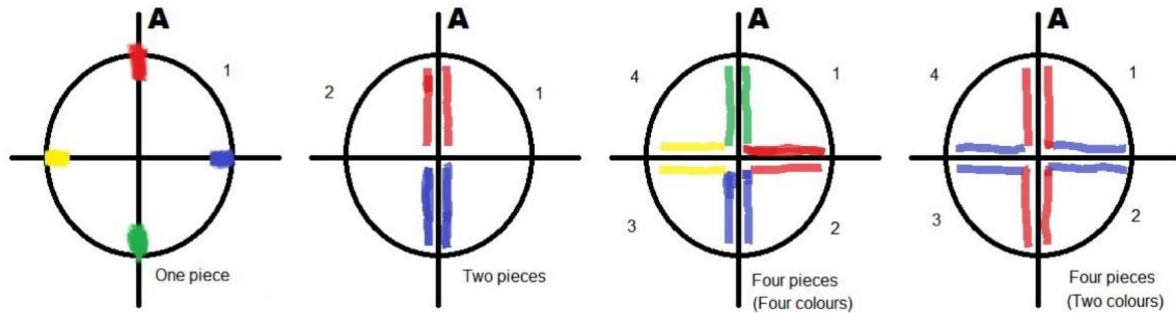
### ***C. Macroscopy***

Before the specimen is prepared for mapping, inking and embedding, the LT needs to describe the specimen macroscopically. The shape and size of the specimen should be represented on the MMS lab form by drawing the specimen received from the surgeon.

### ***D. Mapping and inking***

Mapping and inking of the specimen during MMS can be done by the surgeon or the LT. In the latter case, the MMS surgeon will mark the specimen with a suture at 12 o'clock and bring the specimen in a petri dish to the LT. If the specimen is small and fits on a single slide, the surgeon or LT can maintain the specimen as a single piece and only ink the small notches at noon, 3 o'clock, 6 o'clock and 9 o'clock. Larger specimens can be divided into two, four or more pieces and inked for mapping according to Figure 1. After mapping and inking the specimen, the LT will draw the specimen piece(s) on the MMS lab form indicating the colours used during the inking process so that the MMS surgeon and/or pathologist knows exactly how the tissue is oriented.





**Figure 1.** Examples of techniques for mapping and inking fresh tissue specimens during MMS.

### ***E. Embedding technique***

This step in the lab procedure is the most important step. The LT has to embed the specimen so that both the lateral and deep margins lie 100% flat prior to sectioning the specimen in the cryostat.


There are different ways to embed the specimen:

- Embedding by using microscope glass slides and a spirit level
- Embedding by using an embedding device
- Embedding the specimen right on the chuck in the OCT
- Embedding by using plastic molds and using liquid nitrogen
- Embedding by using steel molds

The two most used ways are embedding by using microscope glass slides and a spirit level or by using an embedding device.

Figure 2 shows the required steps to embed by using a microscope glass slide and a spirit level:

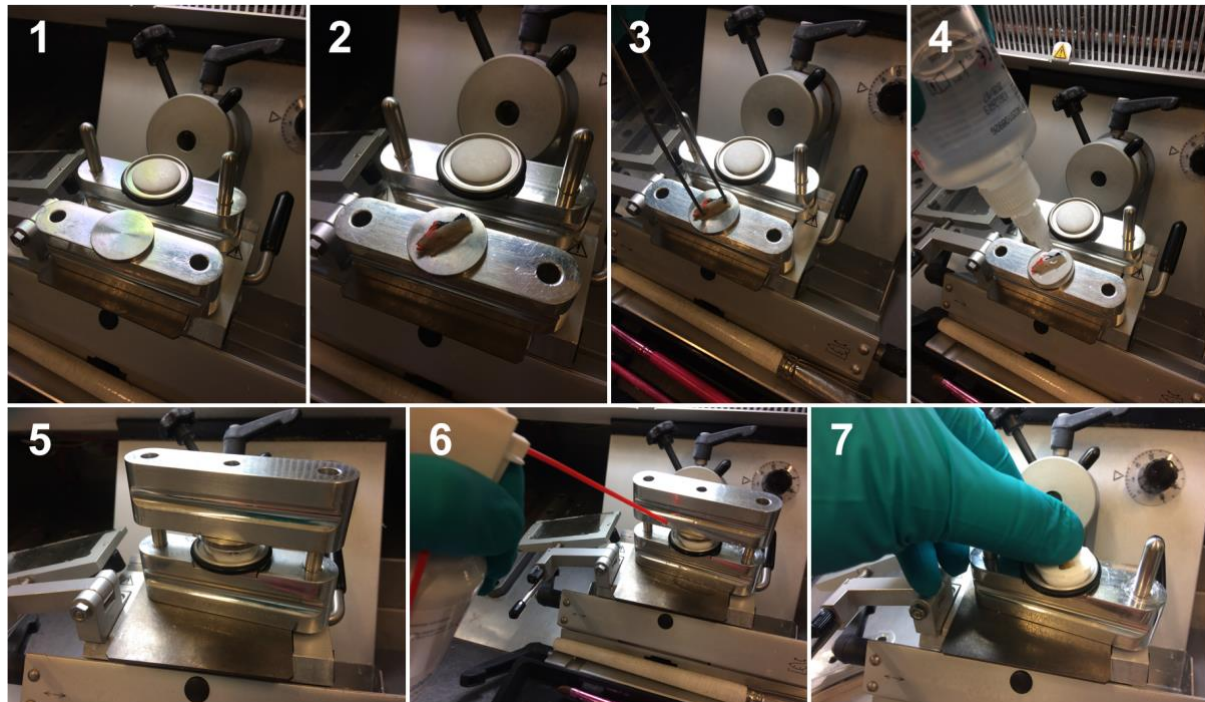
1. Place the slides in the cryostat chamber on the cutting plate.
2. Place specimen with the part that should be sectioned facing the slide.
3. Push the skin edges onto the slide with tweezers.
4. Use sufficient OCT compound around and above the frozen skin specimen.
5. Add OCT compound on the filled chuck
6. Place the frozen specimen on top of the chuck with the slide facing outwards.
7. Try to make the surface horizontal by using a spirit level tool.
8. Cryospray can be used to shorten the freezing process.
9. Remove the slide by heating it with your thumb or by placing the slide onto the skin of your forearm, for example.



**Figure 2.** Embedding tissue with using a microscope glass slide and a spirit level with the steps described above.

Figure 3 shows the required steps to embed by using an embedding device:

1. Place the disk in the adapter and the chuck in the other part of the embedding device.
2. Place piece of skin with the part that should be cut on the embedding disk.
3. Push the skin edges and resection area onto the disk with tweezers.
4. Use sufficient OCT compound around and above the frozen skin specimen.
5. Place the adapter with the embedding disk above the adapter with the chuck and leave it to solidify after freezing.
6. Use cryospray to speed up the freezing process.
7. Remove the adapter of the embedding disk and remove the embedding disk by heating the disk with your thumb.



**Figure 3.** Embedding tissue with an embedding device with the steps described above.

### ***F. Microtomy/cryotomy***

In this step, it is of utmost importance that the entire resection area without any holes including the skin edge (epidermis) and all marking ink are made visible on the slide. Every piece of the specimen will be cut from the resection area (level 1) and upwards in 4-6 levels. Between each level there should be a distance of approximately 100  $\mu\text{m}$ . The thickness of each section should be between 6 and 10  $\mu\text{m}$ . The LT should be conservative when cutting the specimens since the tissue cannot be re-sectioned again later.

The cutting procedure involves the following steps:

1. Put the chuck in the block holder of the cryostat making sure that the skin edge is vertical.
2. Acquire a first section and pass it onto the first microscope glass slide (level 1). The sections should always be placed on the microscope glass slides with the same orientation to avoid confusion when placing the slides under the microscope.
3. Go deeper into the tissue by turning the wheel 8-9 times (approximately 100  $\mu\text{m}$ ).
4. Repeat steps 2 and 3 until you have obtained section levels 2 to 4 or 2 to 6 depending on the amount required by the MMS surgeon.

### ***G. Staining the slides***

Microscopically, fresh frozen tissue specimens are basically colourless, so it is the job of the LT to give the tissue colour in order for the MMS surgeon and/or pathologist to make a histopathological diagnosis under the microscope. The most common stain used in MMS is classical haematoxylin and eosin (H&E) staining (Appendix). Haematoxylin is a stain that used to be made from tree bark and it will colour the nuclei dark purple or blue. Eosin is a synthetic stain that dyes proteins in the cytoplasm, collagen, muscle fibres and more with a red/pink colour. Some MMS labs use toluidine blue.<sup>15</sup>

### ***H. Quality check by microscopy***

After staining and covering the slides, they should be left to dry and the LT should make sure that the slides are labelled with the specific case information. Before taking the slides to the MMS surgeon or pathologist, the LT will check the quality of the slides making sure that all skin edges and all mapping colours are visible. Also, no holes should be present. Review should be done under the microscope using 2.5x, 5x and 10x magnification. If there is something missing, new slides (levels 5-6 or 7-8 depending on the previous number of levels obtained) should be obtained. After the quality check, the slides should be taken to the MMS surgeon or pathologist for examination. The slides with the MMS lab form are evaluated by the MMS surgeon and/or pathologist in order to determine whether the surgical resection areas are clear or not.

### ***I. Consultation with the MMS surgeon and/or pathologist***

It is always important to have good and open communication between the LT and the MMS surgeon and/or pathologist to decide on whether or not margins are clear, ensuring correct tissue orientation and deciding on the next step. When all tumour has been removed, the job of the LT is done. If the margins are not clear, the next stage of MMS will take place and the lab process will start over from the beginning with subsequent rounds until the tumour has been completely removed.

## 5. Other methods of micrographic surgery

This chapter on other methods of micrographic surgery (MS) is based on the recommendations of the German S1 guidelines.<sup>16</sup> Besides MMS on frozen sections there are various techniques combining surgical excision with further macroscopic dissection of the surgical specimens for histopathological processing which may allow for complete or almost complete margin control. With regard to the histopathological processing, a distinction is made between methods that allow for complete examination of surgical margins (Table 1) and methods that have diagnostic gaps (e.g. increased number of vertical sections according to the bread loaf technique or combining vertical sections with additional biopsies from the margins). The ESMS does not consider methods that have diagnostic gaps to be variants of MS.

MS techniques with complete margin control provide the greatest sensitivity possible to ensure actual complete resection. Whether they are significantly more beneficial than incomplete methods regarding the recurrence-free interval has not yet been ascertained by prospective randomised clinical studies. However, when comparing the plethora of data on local recurrences in the literature, methods with complete examination yield much better results than traditional surgical excision.<sup>17-28</sup>

The expertise and experience of both the surgeon and the histopathologist may be ideally unified in the same person: i.e. a MS surgeon (certified by the ESMS). However, many techniques can be performed as a collaboration of two individuals with special expertise: a surgeon and a histopathologist. If so, communication between them is crucial for the quality of these techniques.<sup>29-</sup>

31

Various histopathological processing methods in microscopically controlled surgery are intended to ensure complete surgical tumour removal. In all of these methods, the removed tissue is marked for precise topographic orientation. These procedures differ in terms of the surgical technique employed as well as the method used for histopathological sectioning, both ensuring confirmation of complete resection in different ways.<sup>31-33</sup>

**Table 1.** Advantages and disadvantages of MMS as compared to MS techniques.

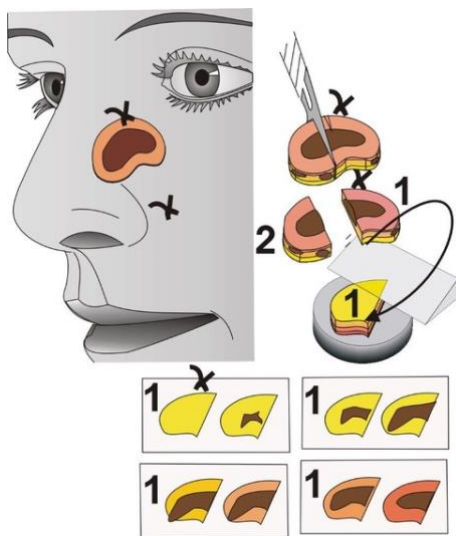
Method	Advantages	Disadvantages
<b>Mohs micrographic surgery</b> (Bowl-shaped excision, cryostat sectioning)	Complete examination of surgical margins. Prompt wound closure on the same day.	Risk of artefacts. Requires equipment and specifically trained staff.
<b>Munich method</b> (Horizontal sections, cylindrical excision, cryostat sectioning)	Clear confirmation of complete excision by visualization of the entire tumour (3D). Prompt wound closure is possible.	Numerous sections have to be assessed. Limited assessment of the epidermis. Interpretation requires special experience.
<b>Margin strip method</b> („Tübinger Torte“) and <b>Muffin technique</b> (En bloc excision, separation of margins and base from the unfixed or fixed specimen)	Complete examination of surgical margins. En bloc excision within a single procedure. Suitable for large (margin strip method) and small (muffin technique) excisions.	Tumour centre of small specimens is harder to assess. Geometric (visual) imagination is required. Requires appropriate training.



The histopathological methods are used in the context of one-stage, two-stage or multiple-stage procedures. Immediate wound closure is basically possible, if there are no disadvantages in case follow-up surgery becomes necessary but only when exact topographic correlation remains possible. Immediate wound closure prior to receiving the histopathological report is not recommended when flaps are to be used for repair. In case of large tumours or problematic locations, final wound closure may be delayed by using suitable protective dressings to temporarily cover the defect. In this kind of procedure, tumour removal and defect closure are performed at different points in time; irrespective of the excision technique used and depending on the situation, wound closure may be achieved by reconstructive plastic surgery procedures, skin grafting or secondary intention healing. If the tumour extends to the surgical margins in the histopathological sections, the tumour-infiltrated margin area or wound base is exactly identified topographically within the surgical defect and re-excised until complete removal is ensured.

### **Horizontal method (Munich Method)**

Derived from the MMS technique, the Munich method is characterised by cutting parallel to the skin surface.<sup>33,34</sup> Unlike MMS, cylindrical specimens with vertical margins are histopathologically processed in the cryostat (Figure 4). This allows for assessment of the entire tumour. Sequential horizontal sections are cut examining intermediate slices of 6-10 µm while discarding sections of about 100 µm in between resulting in a large number of horizontal parallel sections. Although this method does not actually provide 100% margin control, assessment of these selected serial sections from the base of the tumour up to the epidermis allows for evaluation of the three-dimensional growth pattern of the tumour. In case of extensive tumours that do not fit onto the cryostat slide, the tissue is divided into several individual blocks and topographically marked accordingly, rendering more time-consuming histopathological processing.



This method is suitable for histopathologically confirmed epithelial tumours, especially BCC and recurrences thereof. The Munich method is not suited for the histopathological assessment of superficial lesions such as lentiginous melanocytic tumours, extramammary Paget's disease nor Bowen's disease, given that pathological cell structures are difficult or impossible to assess in horizontally processed cryostat sections.

**Figure 4.** Horizontal sectioning according to the Munich method (reprint with permission from Wiley).

### **3D histology**

As an alternative to the aforementioned techniques, a few methods that resemble one another were described very early in the literature: "La Galette"<sup>35,36</sup>, "Tübinger Torte" or "Tübingen tart"<sup>37,38</sup>, the flounder or muffin technique<sup>39-41</sup>, the square procedure<sup>42</sup>, quadrant method<sup>43</sup> and the moat or perimeter technique<sup>44</sup>. These names are sometimes used synonymously and called "3D histology" but designate different techniques with individual advantages and disadvantages. The aforementioned methods basically represent the three-dimensional tumour margins without any gaps. Along with the central section, the histopathologist assesses whether or not tumour components are visible at the excision margins.

In contrast to MMS, curettage of the exophytic tumour components (debulking) is not necessary in 3D histology techniques and the incision is performed perpendicular to the skin surface at a 90-degree angle, which is beneficial with regard to the ensuing reconstructive defect closure. A drawback of using an angled incision lies in the possibility of unnecessary incision of tumour components in the lower dermis. Attempts to avoid this disadvantage by extending surgical margins lead to unnecessarily large wound defects.

Using appropriate surgical margins, the tumour is usually excised *en bloc* in 3D histology. When performing 3D histology, such surgical margins range between 1 and 10 mm, and may be determined on the basis of various factors:

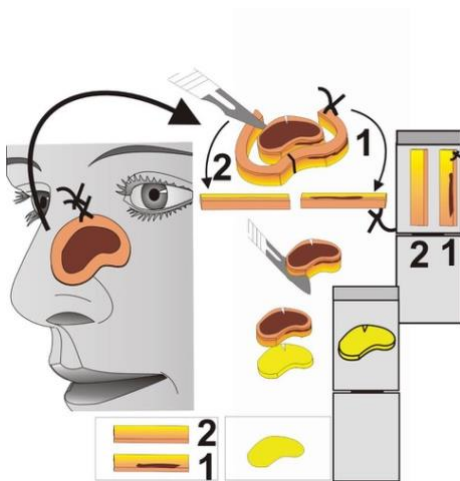
1. Tumour size: The larger the clinically visible tumour, the wider the surgical margins must be. The effect of surgical margins on the defect size diminishes as the area of the initial tumour increases. Thus, unnecessary follow-up surgeries are avoided.<sup>45</sup>
2. Body site: Depending on the functional and aesthetic significance of the affected site, surgical margins may be smaller to preserve unaffected skin. If the affected site is not problematic, surgical margins may be wider in order to reduce the need for follow-up surgeries.
3. Tumour type: Wider primary surgical margins are also recommended for infiltrating tumours.<sup>46</sup>

Intraoperatively, an incision or suture is placed at a defined site as a marker for topographic orientation, usually at 12 o'clock (relative to the cranial vertex). There are various techniques for macroscopically cutting the non-fixed specimen.

In the margin strip method (**Tübinger Torte**), the tumour margins are dissected off of the specimen in strips of approximately 1-3 mm (width), while the base is removed in the shape of a disc. The

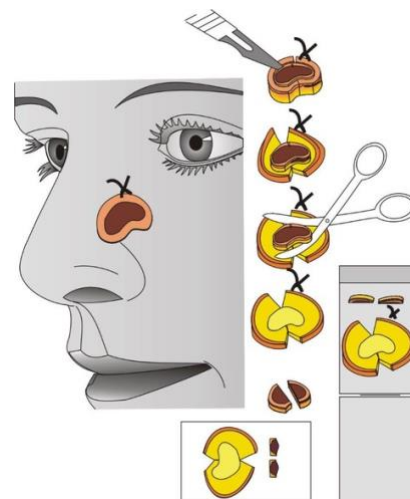
dissected tissue segments are subsequently divided to make them fit into histopathology cassettes for routine processing. Here, rules have been developed to facilitate communication between the surgeon and the histopathologist.<sup>27,40</sup>

Embedding of the margins and the base of the tumour in their unfixed state may be performed by the surgeon or at the histopathology lab (Figure 5).



**Figure 5.** Sectioning according to the margin strip or “Tübinger Torte” method (reprint with permission from Wiley).

For small excisions (up to 2 cm in diameter), the margins and the base may be brought into one plane by incisions using the **Muffin technique** (Figure 6). A representative cross-section through a central part of the tumour can aid in diagnostic classification. Dye marking of the native specimen facilitates topographic orientation in the histopathological sections.



**Figure 6.** Sectioning according to the Muffin technique (reprint with permission from Wiley).

In these 3D histology techniques, the removed tissue is usually fixed in formalin followed by paraffin embedding. Cryostat processing (with the aforementioned advantages and disadvantages) is also possible. Using the paraffin method with rapid tissue fixation in a 60°C formalin solution for two hours, the histopathological sections can be available the next day.

The histopathology lab can also do the macroscopic preparation of the margins and base (margin strip method or “Tübinger Torte” and quadrant technique) on fixed tissue (Figure 8), but this is more difficult and time-consuming. Following fixation, the separated margins and base are first embedded in paraffin. Heated to 65°C, the outer side of the wax-like tissue can then easily be bent into one plane. This procedure makes it easier to send the specimen to a histopathological lab, where sectioning takes place. In the peripheral method, far fewer margins have to be assessed. Similar to the MMS technique, it is not possible to ascertain the distance between the tumour and the excision margins.

**Table 2.** Comparison of MMS and the most commonly used 3D histology techniques (“Tübinger Torte” and “Muffin technique”)

Technique	MMS	“Tübinger Torte” & “Muffin technique”
Debulking	Debulking using a curette	No debulking. Resection <i>en bloc</i> .
Incision	45° angle (bowl shape)	90° to 100° angle
Orientation	Marking corresponding to the histopathological segments (sutures, dye, incisions, photos)	Incision or suture at 12:00 corresponding to the body axis
Preparation	By the surgeon or lab technician on site. The specimens (e.g. quadrants) with their oblique edges are pressed flat and frozen on the cryostat.	By the surgeon or lab technician on site. The specimen is dissected (e.g. “Tübinger Torte” or “Muffin”) and put on a flat plane (paper) in a histopathology cassette, marked for orientation and fixed in formalin.
Procedure	Frozen sections oblique/parallel to the epidermis.	Paraffin sections perpendicular to the epidermis.
Evaluation	By the MMS surgeon or pathologist on site.	By the surgeon or a pathologist off-site.
Qualification	Physician with surgical and histopathological qualification (excision, pathology, reconstruction)	Physician with surgical and histopathological qualification (excision, pathology, reconstruction) or cooperation of physicians with surgical and pathological qualification.
Time	Slides available within about 30 min.	Slides available within about 20 hrs.
Organisation	A patient can be completely treated with multiple operations on a single day.	A patient might be treated with multiple operations on several days.

### ***Other surgical techniques with diagnostic gaps***

Used very frequently, vertical sections using the **bread loaf technique** is claimed to be subsumed under microscopically controlled surgery.<sup>34</sup> Processing of the topographically orientated tissue starts by creating sequential vertical slices with a scalpel. Representative sections are then made from the resulting tissue slices. Due to the serial slices, there are diagnostic gaps. Assuming 1 mm slices and a section thickness of 10 µm, mathematically only 1% of the tumour margins are histopathologically examined. These diagnostic gaps may give rise to the false impression of complete resection. In a prospective, randomised and blinded trial, MS had almost twice the sensitivity of bread loaf microscopy, particularly in the situation of aggressive or infiltrative carcinomas. While having higher sensitivity and accuracy, MS did not require significantly greater time to be carried out than the conventional bread loaf procedure.<sup>47</sup>

### **Special indications for MS**

Just like MMS, MS can generally be recommended when a tissue-preserving surgical technique is required for tumours at problematic locations or when, in case of aggressive growth, local complete resection must be definitively ensured. Given that in some tumour entities subclinical extensions may be better assessed in paraffin sections, MS is sometimes preferable to rapidly frozen sections using a cryostat. The preference for paraffin embedded slides particularly applies to desmoplastic cutaneous squamous cell carcinoma that has infiltrated the subcutis or shows moderate to poor differentiation<sup>48</sup>, Merkel cell carcinoma<sup>49</sup>, extramammary Paget's disease<sup>50,51</sup>, dermatofibrosarcoma protuberans<sup>23,24</sup>, as well as lentigo maligna melanoma and acral lentiginous melanoma<sup>27,52-57</sup>. Gapless 3D histology using paraffin sections is also valuable for recurrent basal cell carcinoma or squamous cell carcinoma<sup>22,46</sup> although no studies comparing outcomes of MS vs MMS exist for these more common indications. In case of osseous infiltration of the tumour, MS is of limited use and marked by increased complexity. Prior to histopathological examination, the osseous components must be decalcified.

### **Documentation during MS**

On the basis of drawings (e.g. operative report, histopathology request form, and histopathology report) and histopathological sections, all methods used in MS must be documented in such a way that the individual steps taken can be readily reconstructed.



## 6. Indications and limitations for Mohs micrographic surgery and other micrographic surgery techniques

### Basal cell carcinoma

BCC is the most common form of skin cancer in lighter skin types and the most common indication for MMS.<sup>58</sup> Various American surgical and MMS societies joined forces in 2012 to publish appropriate use criteria for MMS including 69 clinical scenarios for BCC depending on the area of the body (high, medium or low risk), patient characteristics (e.g. immunosuppression) and tumour characteristics (e.g. aggressive subtypes, recurrence or incomplete excision). They concluded that MMS was appropriately used in 76.8% of these scenarios including all recurrent, primary aggressive, primary nodular, and primary superficial BCCs on high- or medium-risk areas regardless of size or patient type. The only exception was primary superficial BCC  $\leq 0.5$  cm in medium-risk areas on healthy patients.<sup>1</sup> In Europe, however, the recommendations on when MMS is indicated in the management of BCC are more restrictive. British, Dutch and Swedish authors suggest that MMS should generally be reserved for high-risk BCCs in the head and neck area, especially if any of the following clinical and/or histopathological criteria are met<sup>59-61</sup>:

- Localization in the central face, around the eyes, nose, lips or ears (regardless of the size).
- Poor clinical definition of tumour margins.
- Recurrent or incompletely excised lesions.
- Aggressive histopathological subtypes (e.g. morphoeic, infiltrative, micronodular and basosquamous subtypes).
- Perineural or perivascular involvement.
- Size  $>2$  cm.
- When tissue sparing is of great importance (regardless of location).

The number of stages required for complete removal of BCCs with MMS will depend on the indications applied by the surgeon carrying out the procedure. Authors from Rotterdam, The Netherlands found that BCCs located in the H-zone, recurrent tumours, aggressive subtypes and tumours  $>10$  mm were significantly associated with two or more stages of MMS.<sup>59</sup> Paoli et al. reported that at least 2 stages of MMS were needed for clear margins in 87.5% of the 587 cases when applying similar indications for MMS.<sup>60</sup> Alam et al. carried out a survey among American MMS surgeons who reported that BCCs required a significantly lower number of stages when performing MMS on extrafacial areas.<sup>62</sup>

A single randomised, controlled trial has been carried out comparing MMS with surgical excision for the treatment of facial BCCs.<sup>43</sup> The 10-year recurrence risk for primary BCCs after MMS was 4.4% compared to 12.2% for surgical excision, but the difference was not statistically significant. For recurrent BCCs, the 10-year recurrence risk was significantly lower with MMS (3.9%) when compared to surgical excision (13.5%).<sup>11</sup> In retrospective studies, 5-year recurrence risks of 2.1-3.2% have been observed with MMS for aggressive primary facial BCCs and 5.2-6.7% for recurrent facial BCCs.<sup>58,60</sup>

In regards to other MS techniques for BCCs, Boztepe et al. achieved 5-year recurrence rates of 3.3% among 178 primary BCCs and 7.3% among 83 recurrent BCCs using the Munich method.<sup>18</sup> A smaller series of 60 BCCs removed with the Tübinger torte method showed no recurrences after a median follow-up of 53 months.<sup>63</sup> Other authors have reported 5-year recurrence rates as low as 1% after 3D-histology.<sup>22,30</sup>

### Cutaneous squamous cell carcinoma

cSCC is characterised by the malignant proliferation of keratinising cells of the epidermis or its appendages. cSCC usually arises from precursor lesions such as actinic keratosis or Bowen's disease

(SCC *in situ*) but can also grow *de novo*. It is the second most common non-melanoma skin cancer (NMSC).<sup>64</sup>

In contrast to BCC, which rarely metastasises, cSCC can metastasise initially to regional lymph nodes and subsequently to distant sites. The rate of metastasis in cSCC has been estimated to range from 2% to 5%. Brantsch et al. prospectively analysed factors predicting regional lymph node metastasis in 615 patients with cSCC. The mean and median follow-up time was 43 months and 26 patients (4.2%) developed regional metastases. Four main prognostic factors predictive of regional metastases on multivariate analysis have been identified: increased tumour thickness (HR 4.79), localization on the ear (HR 3.61), increased tumour diameter (HR 2.22) and presence of immunosuppression (HR 4.32). Patients in this series with cSCC with a tumour thickness  $\leq 2.0$  mm never developed regional metastases and less than 2% developed metastases if the primary tumour was  $\leq 2$  cm in diameter. In contrast, regional metastases developed in 16% of patients with cSCCs that were  $>6.0$  mm thick and in 3.8% of patients with intermediate tumour thickness (2.1-6.0 mm). This also occurred in 8% of patients with a tumour diameter of 2.1-5.0 cm and in 20% of the cases with tumours  $>5$  cm. Regarding tumour location, 10% of patients with a primary cSCC located on the ear developed metastases. Finally, 16% of immunosuppressed patients developed regional metastases. Findings from this study suggest that tumour size (thickness and/or diameter) are important features in metastasis prediction<sup>65</sup>. Different prognostic classifications have been proposed that allow a risk stratification taking into account that cSCCs encompass tumours with very different aggressiveness.<sup>66,67</sup>

According to the recently published European Dermatology Forum guidelines, the treatment of choice for cSCC is still surgical excision, which allows for confirmation of tumour removal and high effectiveness. The excision margins should be adapted to the clinical and histopathological features of the cSCC, including the diameter and the differentiation of the tumour.<sup>68</sup> Surgical removal of primary cSCCs can be done with standard surgical excision followed by conventional post-operative histopathologic assessment of the margins (conventional histopathology), with MMS and other MS techniques. The optimal treatment modality depends on the tumour location and stage, but also on the patient's comorbidities and preferences.

Although no well-defined criteria have been defined to establish when MMS should be chosen instead of standard surgical excision and vice versa, both methods are considered the standard of care in the management of cSCC.<sup>69</sup> Sixteen studies reported outcomes after MMS.<sup>70</sup> In a seminal series of papers, Mohs reported cure rates at five years for previously untreated cSCCs of the trunk and extremities (95,7%); of the ear (96,6%); of the face, scalp and neck (97,8%); of the eyelid (98,5%) and of the nose (97,8%). A pooled cure rate at five years for the 2133 SCCs at all sites was 97,4% (95% confidence interval 96,2%-98,3%,  $I^2 = 48\%$ ). Ten studies reported local recurrence rates ranging from 0 to 5,7%. The pooled average local recurrence was 3% (2,2%-3,9%,  $I^2 = 0\%$ ). In a large multicentre case series study of 1253 patients, with at least 5 years follow-up, the recurrence rate was 2.6% in patients with primary cSCC and 5.9% in patients with recurrent cSCC ( $P < 0.001$ ).<sup>25</sup> However, MMS is still debated for very high-risk cSCC due to concerns about the possible presence of in transit metastases and skip lesions and the more challenging histopathological margin interpretation. No randomised, prospective studies have been performed comparing MMS or MS with standard excision in cSCC. To date, there are no prospective comparative studies focusing on long-term recurrence rates that have demonstrated a significant advantage of MMS or MS.<sup>71,72</sup> However, MMS should be considered as the treatment of choice mostly in cases of cSCCs at sites where broad excision margins can cause significant functional impairment (tumours on the eyelids, lips, ears, central part of the face or nails) and should be performed by a trained MMS surgeon. The UK guidelines recommend MMS in some high-risk cSCC cases following multidisciplinary team discussion.<sup>73</sup>

For certain subtypes of cSCC (e.g. spindle cell subtypes) and in the presence of perineural invasion (PNI), frozen section interpretation may be difficult, whereas permanent paraffin sections as performed in several other MS techniques may eliminate the potential for freeze artefacts. Sometimes, a final stage of permanent sections is therefore used by MMS surgeons when equivocal frozen section interpretation is encountered.<sup>74</sup> PNI, which occurs in approximately 2.5%-14.0% of cSCCs is associated with a high rate of recurrence (28.6% vs 13.6%) and metastasis (32.8% vs 9.2%), especially when the tumour is located in the head and neck region and when the affected nerve has a larger diameter. When conventional surgery is applied, these tumours present a rate of recurrence of up to 47.2%. By contrast, the recurrence rates with MMS vary between 0% and 8%.<sup>75</sup> In a prospective study, tumour sizes before excision, postoperative defect sizes, subclinical extension, and mean number of MMS stages were significantly larger in cases with PNI compared with cases without PNI ( $P<0.0001$ ,  $P<0.0001$ ,  $P=0.002$  and  $P<0.0001$ , respectively). Most patients with PNI (52.9%) were treated with adjuvant radiotherapy. In all, 25 patients completed a 5-year follow-up after MMS, and two of them (8.0%) were diagnosed with a recurrence.<sup>26</sup> Although there are no comparative studies between standard excision and MMS for cSCCs with PNI, the available data suggest that total margin control is a more reasonable approach in such tumours.

### **Malignant melanoma**

MS is helpful to ensure complete excision of poorly demarcated subtypes of malignant melanoma, especially in lentiginous types with continuous subclinical spread (e.g. lentigo maligna melanoma and acral lentiginous melanoma). It is not suitable for superficial spreading melanoma or nodular melanoma as these tumour types may present subclinical skip lesions or satellites.<sup>52,56,76,77</sup>

Retrospective studies on lentigo maligna melanomas localised in the face, on the nose and on the ears, lentigo maligna melanoma as well as acral lentiginous melanoma have demonstrated that the reduced safety margins used when performing MS with paraffin techniques were not associated with increased local recurrence or reduced overall survival when compared to the larger safety margins applied during standard excision.<sup>16,27,52,55,78</sup>

Excision of subungual melanomas using MS with subsequent tumour-free margins surrounding the nail matrix has been shown to be a safe strategy which does not compromise the patient's prognosis and allows for function and cosmesis of a finger or toe to remain preserved. Amputations for subungual melanoma should be reserved for advanced cases with bone or joint involvement.<sup>55,78,79</sup>

The German S3-Guidelines on malignant melanoma recommend 3D histology techniques for lentigo maligna melanoma and acral lentiginous melanoma, especially in special anatomic locations in which reduced safety margins (e.g. face, ears, fingers or toes) may help preserve function and cosmesis while not increasing the risk of local recurrences or decreasing overall survival. However, informed patient consent should be obtained prior to MS since outcome data are limited.<sup>80</sup>

### **Extramammary Paget disease**

Extramammary Paget disease (EMPD) is a rare intraepithelial neoplasm of the skin characterised by ill-defined margins and high recurrence rates after wide local excision (WLE). A comprehensive systematic review and individual patient data meta-analysis was performed in 2013 including all available clinical studies and case reports with 5 or more subjects. Eight studies (3 retrospective studies and 5 case series) were identified and included a total of 81 patients with 90 cases of EMPD treated with MMS. The overall recurrence rate was 12.2% correlating with an estimated 5-year tumour-free rate of 83.6% by using Kaplan-Meier analysis. The treatment of EMPD with MMS resulted in significantly lower recurrence rates than WLE in this meta-analysis of 3 observational studies with comparators (odds ratio 0.20; 95% confidence interval 0.05-0.81).<sup>81</sup>

### Adnexal carcinomas

Adnexal carcinomas (ACs) are rare cutaneous malignancies of sweat gland or pilosebaceous origin. Optimal treatment and metastatic potential of ACs are poorly defined. The rarity of ACs and the lack of comparative data on treatment makes conclusive recommendations on treatment difficult. Recent large case series and reviews suggest MMS is a useful and possibly superior treatment for ACs and should be considered when primary cutaneous disease is suspected.<sup>82</sup>

- **Sebaceous carcinoma** treated with MMS has been shown to recur and metastasise in 6.4% and 3.7%, respectively.<sup>82</sup>
- **Primary cutaneous mucinous carcinoma** treated with MMS recurred and metastasised in 9.6% and 6.4%, respectively.<sup>82</sup> In a large meta-analysis, most primary cutaneous mucinous carcinomas were treated with surgical excision (85.5%), with only 9.4% of cases treated with MMS. Only two of the 15 cases treated with MMS (13%) recurred, and none metastasised. In contrast, traditional WLE led to a recurrence or metastatic rate of 34%.<sup>83</sup>
- After MMS, 4.7% of **microcystic adnexal carcinoma** (MAC) recurred with no reported metastases in a review of 191 cases.<sup>82</sup> However, MAC is characterised by aggressive local infiltration, including a high propensity for PNI. MMS with frozen sections is reliable for treating primary MAC in which PNI is not present on a diagnostic biopsy. Previous surgery and PNI were associated with greater risk of persistence in periocular MAC. In these patients, it may be appropriate to consider MMS with paraffin-embedded sections, possibly as an extra layer after apparent clearance on frozen sections. Further excision of orbital contents should be considered in periocular MAC that infiltrate the deep orbital fat or are noted to have PNI.<sup>84</sup>
- Recurrences and metastases of **trichilemmal carcinoma** or **hidradenocarcinoma** have not been reported after MMS.
- **Eccrine porocarcinoma** (EPC), also known as **malignant eccrine poroma**, is derived from the eccrine sweat glands and has an incidence of 0.2 per 100,000 persons. WLE has traditionally been the predominant therapeutic option, and it has been associated with recurrence rates of 20%, distant metastatic rates of 12% and mortality rates as high as 50%. A 3-mm margin has been advocated for biopsy-proven EPC and an additional 5-mm margin with a modified MMS technique for infiltrative and pagetoid variants.<sup>85</sup> MMS has emerged as a viable therapeutic option in EPC. In a recent review by Song and colleagues, only 1 nodal recurrence and no local recurrences were reported among 21 cases treated with MMS.<sup>86,87</sup> In addition, three subsequent studies of 12, 9, and 5 cases of EPC showed only 1 case with regional lymph node metastases.<sup>88-90</sup> Overall, only 2 of 47 EPC cases (4.2%) treated with MMS, developed regional lymph node metastases with no patients having local recurrence, distant metastases, or disease-specific mortality.
- Rare publications of MMS without reports of recurrences exist for squamoid eccrine duct tumour, pilomatrix carcinoma, spiradenocarcinoma, malignant hidroacanthoma simplex, syringomatous carcinoma, aggressive digital papillary adenocarcinoma.

### Dermatofibrosarcoma protuberans

Dermatofibrosarcoma protuberans (DFSP) is a rare, locally aggressive cutaneous malignancy characterised by slow infiltrative growth and a low risk for distant metastases. WLE with surgical margins of 2-3 cm is considered the standard surgical treatment but local recurrence is reported to occur in up to 60%, with most recurrences occurring within 3 years. Aggressive local recurrence following inadequate resection occurs as a result of infiltrative lateral projections of DFSP which can be missed clinically and histopathologically, resulting in high local recurrence rates following WLE. MMS has emerged as an alternative to WLE for DFSP with case series reporting low rates of local recurrence.<sup>91</sup> Among 19 non-randomised non-comparative studies, 7 studies used a frozen section histopathologic assessment technique, 6 studies used formalin-fixed section techniques, and in a further 6 studies the technique was not clearly specified.<sup>92</sup>

Local recurrences of DFSP occur if inadequately excised. A recent retrospective comparative trial was published with long-term follow-up data for patients treated with MMS (n=67) and WLE (n=91) with mean follow-up times of 4.8 and 5.7 years, respectively. Twenty-eight patients (30.8%) had recurrences after WLE (mean follow-up of 4.4 years), whereas only 2 (3.0%) treated with MMS recurred after 1.0 and 2.6 years. Recurrence-free survival rates at 1, 5, 10, and 15 years were significantly higher with MMS ( $p < 0.001$ ). Mean preoperative lesion sizes were similar (5-6 cm) between the 2 groups, whereas mean (standard deviation) post-operative defect sizes were 10.7 (4.3) cm and 8.8 (5.5) cm for WLE and MMS, respectively ( $p = 0.004$ ). Primary closure was used for 73% of MMS cases, whereas WLE more commonly required flaps, grafts or other closures (52%). Two MMS stages were typically required for margin control. Despite the inconsistency of surgical techniques used, margin control using histopathological assessment either by frozen section or using paraffin-embedded tissue can reduce the recurrence rates of DFSP at any site.

There are practical limitations with MMS. For example, small fascicles of tumour may be difficult to distinguish from scars on frozen sections. It is also logistically difficult to process large tumours with MMS as large quantities of fat at the deep margin require adequate time to freeze which lengthens tissue turn-around time. These difficulties can be avoided by using MS with paraffin sections. Three studies specifically used CD34 immunostaining to ensure margin control, which may improve the guarantee of complete tumour removal. A recent study comparing MMS (n=30) to MS (n=41) for DFSP showed similar recurrence rates after approximately 2 years of follow-up (3.3% and 7.3%, respectively).<sup>93</sup>

### **Merkel cell carcinoma**

Merkel cell carcinoma (MCC) is a rare, aggressive malignant skin neoplasm. Traditionally, WLE has been used for local control. However, the tissue-sparing capability of MMS and the greater certainty of complete tumour removal offer a potential advantage over WLE. The available literature on the use of MMS for initial treatment of the primary tumour in patients with MCC is sparse. A multicentre, retrospective study by Boyer et al., demonstrated good local control of primary MCC when treated with MMS. This study included 45 patients treated with MMS with 20 of these patients also receiving adjuvant radiation. No local recurrences or metastases were observed in the group treated with MMS and radiation, whereas one local recurrence and three in-transit metastases occurred in the group treated with MMS alone.<sup>17</sup> A retrospective study of 240 cases by Tarantola et al. reported no difference in overall survival between MMS and standard surgical excision.<sup>94</sup> In a recent retrospective chart review of 22 patients with cutaneous MCC treated with MMS, Kline et al. showed an overall local recurrence rate of 5%. The overall rate of biopsy-proven metastases to regional lymph nodes was 14% but no cases of distant metastases were documented.<sup>95</sup> MMS therefore compares favorably with standard surgical excision. Radiotherapy after MMS may further reduce the occurrence of in transit metastases and nodal disease.<sup>96</sup>

### **Other conditions**

Other conditions for which MMS may be discussed include: angiomyxoma, intravascular papillary endothelial hyperplasia, malignant glomus tumour, recurrent glomus tumour, red tattoo reaction, cutaneous lymphadenoma, cutaneous alternariosis, granular cell recurrent giant cell fibroblastoma, onychomatricoma, cellular neurothekeoma, aneurysmal dermatofibroma, cutaneous malignant mixed tumour, retiform hemangioendothelioma, adenomatosis of the nipple, myxoid neurofibroma.



## 7. Adjuvant therapy in MMS

Although MMS is capable of curing BCC and SCC with the highest cure rates, an adjuvant treatment can be considered necessary or advisable in some cases. It is also important to keep in mind that large tumours (not necessarily with aggressive subclinical extension) are at a 50 times higher risk for postoperative complications after MMS, due to their increased size and need for advanced repair.<sup>97</sup> There are a number of treatment options available for minimising the chance of recurrence, reducing the tumour defect and/or combinations. It should be noted, however, that the use of neoadjuvant therapy prior to MMS to reduce tumour size conveys a potential risk of incomplete cure, leaving behind independent tumour nests, which could lead to false-negative results if MMS is performed afterwards.<sup>98</sup>

### Topical treatment of superficial BCC pre- or postoperatively

MMS is usually used for treating facial BCCs with a more infiltrative or aggressive growth pattern, while superficial and nodular BCCs are treated with standard surgical excision. However, it is well known that there can be a discrepancy between the histopathology of BCC in the preoperative biopsy and the intraoperative histopathological diagnosis. It was shown that 35% of BCCs consist of mixed subtypes.<sup>99</sup> MMS is unique in identifying this during surgery since MMS combines surgery with instant histopathology of frozen sections. In a recent study, 50% of the MMS cases for facial BCCs showed a different subtype than in the original biopsy. Of these, 33% showed a more aggressive subtype and 17% a less aggressive subtype.<sup>100</sup> For facial BCCs with mixed histopathological subtypes, further MMS might be considered inappropriate in the case that the invasive tumour is removed and only residual superficial BCC is remaining since superficial BCC can be effectively treated non-surgically. Both pre- and postoperative topical treatment options are available for the superficial parts of BCCs with a mixed subtype.

The greatest advantage of topical treatment options like photodynamic therapy (PDT), imiquimod 5% cream and 5-fluorouracil cream is the preservation of skin. A disadvantage is the lack of histopathological examination and confirmation of the tumour eradication. In selected cases, a combination of MMS with superficial treatment modalities may be beneficial. When the histopathology slides only show superficial BCC remaining in the peripheral margins of the excised tissue during MMS, the surgeon has the option to further surgically remove the tumour with an extra MMS stage, or he/she may choose to further complete the tumour treatment non-surgically. The decision is based on the patient profile, tumour characteristics and the surgeon's preference. A smaller surgical defect will often result in better cosmetic outcome. The chance of recurrence has to be taken into account when an adjuvant non-surgical treatment is chosen. In recurrent tumours, however, histopathological confirmation of complete tumour removal is preferred with a 100% examination of the tumour margins. In these cases, non-surgical treatment is not advised.

Individual topical treatments have different advantages and disadvantages. PDT is usually performed twice and large areas can be treated with high compliance. Some patients experience a burning sensation during treatment. The skin becomes erosive and then reepithelialisation will take place. Imiquimod 5% and 5-fluorouracil cream, however, are therapies with a duration of 6 weeks or more and require patient compliance. The skin becomes irritated, itchy and erosive, then reepithelialisation will take place. Overall, patients experience no pain.

**PDT** is a pharmacological treatment modality predominantly for superficial and to a lesser extent nodular BCCs.<sup>101</sup> Following absorption of the applied topical photosensitiser, destruction of targeted cells and apoptosis occurs as soon as the area is activated by a specific light source. PDT works through the formation of endogenous photoactive porphyrins. The main advantage is that it results in excellent cosmesis with little to no scarring. PDT can be performed before or after MMS. PDT has a limited role as a pre-treatment to MMS but may be used in selected cases, particularly for large

superficial tumours.<sup>102</sup> In four cases of facial mixed type BCC treated with MMS to clear all non-superficial BCC and PDT as adjuvant therapy for the remaining superficial tumour parts, smaller wound defects and therefore better cosmesis could be achieved. No clinical recurrences were seen during the follow-up time of 13-27 months.<sup>103</sup> This MMS-PDT approach may lead to excellent cure of the tumour with maximal conservation of the skin and excellent cosmetic results, but more research is needed before recommending this as a standard of care.

**Imiquimod** acts as an immune response modifier targeting toll-like receptors 7 and 8, although the exact mechanism of action is not fully known.<sup>104</sup> In a recent study, the long-term effects of topical imiquimod was shown for various facial BCC subtypes. A mean follow-up time of 72 months showed a 79% cure rate.<sup>105</sup> In a randomised controlled trial, imiquimod was found to be superior to PDT.<sup>106</sup>

The use of imiquimod cream before MMS might reduce tumour volume and facilitate the procedure so that fewer stages would be required, resulting in a smaller defect and less extensive surgical reconstruction. In a randomised study, the use of imiquimod as a pre-treatment to reduce tumour size was shown to be possible.<sup>107</sup> Studies in which the complete area after treatment with imiquimod was excised did in some cases show remaining tumour nests which were found in the dermis.<sup>108</sup> In another study, topical imiquimod was used after incomplete MMS and did not show any recurrences during a follow-up of 13-30 months.<sup>109</sup>

**Ingenol mebutate** is extracted from the sap of the plant *Euphorbia peplus*, which is known to have therapeutic effects on various cutaneous neoplasms including cancerous lesions.<sup>110</sup> Recently, ingenol mebutate was described for patients with Gorlin's syndrome.<sup>111</sup> In these patients, combinations of destructive, topical and surgical treatments are often used. Invasive tumours require surgery or MMS, whereas superficial BCCs can be treated with topical therapies. To date, however, there are no studies on adjuvant treatment with ingenol mebutate prior to or after MMS and therefore it cannot be recommended.

#### **Adjuvant therapy for advanced BCC**

Advanced BCC encompasses a heterogeneous group of cases, including metastatic BCC as well as locally invasive, large, deep, aggressive and/or recurrent tumours. To achieve a higher cure rate and/or prevent severe disfigurement, adjuvant treatment for these tumours can be suggested. Several therapies are being investigated worldwide for the treatment of advanced BCC.<sup>112</sup>

**Superficial radiotherapy, electron beam therapy, and brachytherapy** are all used for the treatment of BCC.<sup>113</sup> Radiotherapy is an important adjuvant tool for the treatment of NMSC.<sup>114</sup> Radiotherapy is an option for patients not amenable to clear by MMS, including patients for whom further surgery/MMS is contraindicated and patients with PNI. It is important to recognise that BCC with PNI have a higher recurrence rate than BCC without PNI. PNI is more frequently associated with aggressive BCC subtypes, including infiltrative, morphoeic, sclerosing and micronodular variants. Incidental PNI in BCC has shown to have a good outcome with either MMS alone or standard surgical excision plus adjuvant radiotherapy.<sup>115</sup> In the case of positive margins in MMS, radiotherapy can be used as an adjuvant treatment.<sup>116</sup>

**Hedgehog pathway inhibitors (HPIs)** have proven to be an efficacious treatment option for patients with advanced BCC. Emerging data may help clinicians to determine which patients will benefit the most from HPI therapy in combination with MMS. Patients on HPI therapy often discontinue treatment due to accumulation of adverse effects.<sup>117</sup>

**Vismodegib** is an oral HPI approved for the treatment of locally advanced and metastatic BCC. The use of HPIs as a neoadjuvant therapy to surgery could also prove beneficial in some cases and help to reduce the defect associated with complex and extensive surgery. Ally et al. evaluated the reduction

of the surgical defect area when treating 15 patients with high-risk BCCs for 3 to 6 months with neoadjuvant vismodegib. The surgical defect size was reduced by 27% in the 11 patients who completed the trial. Only one patient experienced a recurrence (at 17 months).<sup>118</sup> Another case report shows that in locally advanced BCC, neoadjuvant therapy with vismodegib can shrink the tumour size by more than 80% of the visible lesion within 10 months of treatment.<sup>119</sup> An important drawback might be the fact that tumours can become resistant to vismodegib. In a study, neoadjuvant vismodegib was used for a locally advanced BCC of 13x17 cm on the scalp to shrink the tumour prior to surgery. A new BCC developed during vismodegib therapy which was resistant to the drug.<sup>120</sup>

**Sonidegib**, another oral HPI, has a similar safety profile to vismodegib, but studies on its use as a neoadjuvant treatment prior to MMS are lacking.

The side effects for both vismodegib and sonidegib are muscle spasms (approximately 50%); alopecia (50%); dysgeusia (40-60%); nausea 30-45%); elevated creatine kinase (30%) and fatigue (30%). The more severe side effects are: elevated creatine kinase and rhabdomyolysis (1-3%).<sup>121</sup> Furthermore, both drugs also carry a risk of severe birth defects or fetal death when a pregnant woman is exposed to them.<sup>122,123</sup>

Combination therapies are another treatment strategy that could result in improved efficacy with HPIs in advanced BCC. There is substantial evidence reporting crosstalk between hedgehog signalling and other pathways in several other cancers and enhanced efficacy of the combination therapy over monotherapy.<sup>124</sup>

#### **Adjuvant therapy for cutaneous squamous cell carcinoma**

Typically, cSCC has a higher incidence of PNI than BCC, with reported rates ranging from 2.5% to 14% in cSCC.<sup>125</sup> The use of standard excision alone is considered a risk for cSCC patients with PNI and postoperative adjuvant radiotherapy is often recommended. In an evaluation of the literature (from 1960-2005) the difference between MMS versus standard excision with or without radiotherapy for cSCC with PNI was shown, with local control rates from 92% to 100% for MMS, compared with control rates from 38-87% for standard excision.<sup>126</sup>

Neoadjuvant intralesional methotrexate can also be an option before removing cSCC with MMS or MS. A total of 86 patients diagnosed with infiltrating cSCC were included in a single, retrospective observational study, comparing surgery with or without neoadjuvant intralesional methotrexate. It was shown that neoadjuvant methotrexate can reduce the presurgical size of cSCC and could simplify the subsequent surgery.<sup>127</sup>



## 8. Patient Perspective

Although rarely life-threatening, NMSC can have negative effects on the patients self-esteem as it frequently affects visible parts of the body, such as the head and neck area.<sup>128-130</sup> MMS is associated with high levels of patient satisfaction, with over 95% of patients reporting good or excellent functional and aesthetic outcomes.<sup>131</sup> MMS and excision appear to have equal outcomes on skin-related quality of life, as well as the general well-being of the patient.<sup>132,133</sup> Nevertheless, MMS cannot be performed in every clinical centre and is more expensive than a standard surgical excision.

### ***Patient satisfaction***

Patient satisfaction after MMS depends on several variables. Asgari et al. identified different variables that influence short-term (after one week) and long-term (after 1 year) patient satisfaction after MMS. In fact, results of the study revealed that better preoperative skin-related quality of life, more than 3 intraoperative MMS stages, no bother from bleeding, and perceived involvement in care led to better short-term satisfaction after MMS.<sup>134</sup> Interestingly, patients who were married appeared to have a better long-term patient satisfaction. It has previously been shown that marital status leads to better patient satisfaction among cancer patients. This is not illogical, since a social network is known to improve quality of life and mental health by providing emotional support to the cancer patient.<sup>135</sup>

Results in the investigated literature differ regarding the influence of the number of intraoperative stages on patient satisfaction. Asgari, et al., showed that patients who underwent 3 or more intraoperative MMS stages appeared to experience higher long-term satisfaction. However, a recent review in the British Journal of Dermatology showed that there was no difference in patient satisfaction associated with the number of stages.<sup>131</sup>

Previous studies have shown that preoperative skin-related quality of life significantly influences short-term and long-term patient satisfaction.<sup>132,136,137</sup> Patients with low preoperative skin-related quality of life are generally less satisfied with the medical care with which they are provided and with the physician's interpersonal skills. It is crucial for the dermatologist to identify these patients to optimise patient satisfaction. Hence, it might be helpful to include a short skin-related quality of life questionnaire in order to help identify these sample patients and improve their skin-related quality of life. Lee et al. showed that the patient experience with the surgeon and staff also had a positive influence on how they perceived the surgical treatment of their skin cancer in the facial area.<sup>128</sup> Asgari et al. found that patients were generally satisfied after their surgical treatment of NMSC, but were more satisfied with the interpersonal approach, communication and financial aspects of their care.<sup>132</sup>

### ***Lengthy procedure***

MMS is a lengthy procedure, with most patients leaving the hospital after approximately four hours.<sup>131</sup> A high portion of their journey is spent in the waiting room, a period which could contribute to patient anxiety and perceived satisfaction with treatment.<sup>138</sup> Providing thorough pre-operative information to clarify expectations as well as a comfortable and welcoming waiting room could enhance patient experience.

### ***Complications***

The complication rate (e.g. infection) is relatively low in dermatological surgery. However, a higher amount of concerns was elicited when patients were asked to report their problems and complications.<sup>128</sup> Clinicians might underestimate adverse events experienced by patients, thus it is crucial to identify them by having correct patient satisfaction measurements tools. In a study by the British Association of Dermatologists, there were no major recorded complications aside from infection and minor superficial skin necrosis. Interestingly, there was also no difference in patient satisfaction scores or complication rates between patients younger and older than 80 years.<sup>131</sup>

### ***Cosmetic result***

MMS is known to produce improved cosmetic results.<sup>130</sup> Lee et al. showed that the complete resection of the lesion is most important from the patient perspective, regardless of the cosmetic result. However, good cosmetic results lead to higher quality of life. The location of the tumour also made participants self-conscious with patient satisfaction being higher when the scar was small and located away from the central face. Furthermore, a noticeable scar can be a source of distress. Although facial scars can have a negative effect on self-esteem and confidence, they don't have psychological or social effects.<sup>128</sup> In a large questionnaire study including more than 5,500 participants who had undergone MS for BCCs or SCCs in the head and neck region, the cosmetic result was deemed to be good or excellent in 81.4% of cases, satisfactory in 13.6% and mediocre or poor in <5%.<sup>139</sup>

### ***Improving patient satisfaction***

As previously mentioned, patient satisfaction depends on multiple factors. The dermatologist is challenged to identify and anticipate what these factors are in order to maximise patient satisfaction. A thorough pre-operative consultation, in which the expectations and skin-related quality of life are being investigated, possibly with the help of specialised and standardised questionnaires, might be useful to improve the patient satisfaction. For example, a recent study has shown that a telephonic follow-up after MMS appears to be a cost-effective, time efficient way to improve patient satisfaction.<sup>140</sup>

In summary, MMS is associated with excellent patient satisfaction, regardless of the age of the patient. The biggest advantage of MMS is the low recurrence rate, which gives a feeling of safety to the patient. Since MMS is a one-day procedure, it gives the patient the opportunity to have this feeling of safety within one day rather than with classic excision in which patients must wait for weeks or months until the pathology report is ready or until re-excision (when needed) takes place. Because MMS is tissue-sparing, it gives smaller scars. Most importantly, patients highly value the more reliable guarantee of a complete resection.

## 9. Current use in Europe, ESMS certification

After its first description by Frederic Mohs in the 1930s, the MMS technique underwent many modifications by its users and is today considered the standard of care for many forms of BCC and other tumours in the USA with more than 5,000 dermatologists practicing the technique. It is estimated, that 36.4% of all epithelial tumours in the USA are treated with MMS.<sup>141</sup> Several influential European dermatosurgeons learnt the technique in the USA in the 1970s and started practising it in their home countries thereafter. Since the foundation of the ESMS in 1990, the use of the technique has started to expand to more and more European countries. It was adopted most quickly in the Netherlands, Portugal, Spain, Sweden and the United Kingdom. In 2018, for example, there were 51 MMS surgeons certified by the ESMS in the Netherlands. In many other European countries, the technique spread more slowly but is still practiced in many centres, such as in Switzerland, France, Denmark or Belgium. In some countries, most notably in Germany, other forms of MS, involving paraffin sections with delayed reading of the slides are more commonly used. This is mostly due to long-held traditions that led to the development of different workflows as described previously. Furthermore, reasons for this preference might include different healthcare and billing systems which favour in-patient treatments as well as restrictions for dermatologists to sign histopathology reports.

The reading of the histopathologic slides by the dermatosurgeon is an important part of MMS. Besides the aspects of economic efficiency and saving time, the surgeon gets a clear three-dimensional image of remaining tumour in the margins which allows for the most precise and therefore tissue-sparing excision of additional sections. However, the reading of horizontal frozen sections is difficult and requires specialised training. In all European countries, histopathology of the skin and appendages and skin tumours are an important part of dermatology training. The UEMS core curriculum for Dermatology and Venereology includes dermatohistopathology of skin tumours and advanced knowledge of the biology of all skin tumours. Reading of dermatohistopathologic slides of skin tumours is therefore one of the core competencies of dermatologists and in particular of MMS surgeons. Thus, it is of great importance that the dermatosurgeon is allowed to read his own slides in order to increase efficiency and the accuracy of the MMS procedure. In countries where histopathology reports can only be signed by pathologists, MMS can still be performed but there has to be a second reading of the slides by a pathologist which can also be considered as an additional measure for quality assurance.

In order to guarantee the quality of MMS surgical interventions, certain requirements have to be met by the surgeon performing the procedure as well as by the infrastructure it is performed in. The surgeon needs to be well-trained both in dermatosurgery as well as in dermatohistopathology. The ESMS has contributed to this quality control by establishing standards for how the procedure is performed and the necessary training. Members of the ESMS must fulfil certain criteria in order to become a certified MMS or MS surgeon. They must be dermatologists who have performed at least 100 MMS/MS procedures under the supervision of a certified Mohs trainer and be recommended by two certified members of the ESMS or at least one ESMS board member. Furthermore, the procedure must be carried out in an adequately equipped procedure room suitable for dermatological surgery located adjacent to (or in close proximity to) a Mohs laboratory. If the criteria cannot be fulfilled, for example because there are not sufficient Mohs trainers in a particular country, certification can be obtained by demonstrating the fulfilment of the quality criteria in an audit with a site inspection carried out by surgeons appointed by the ESMS board.

By 2018, 123 dermatosurgeons in Europe have been certified as Mohs or micrographic surgeons by the ESMS. This continuously growing number of persons committed to delivering the highest of standards of care for skin cancer patients shows that there is a trend in Europe to adopt MMS as a standard of care for many forms of skin cancer.

## 10. The future of MMS and MS

New methods such as confocal laser scanning microscopy (CLSM) have been used intraoperatively to directly evaluate tumour margins of BCC. While reflectance-mode CLSM had a certain degree of specificity, its sensitivity has not been sufficient for small tumour extensions.<sup>142-144</sup> The first publications on fluorescence-mode CLSM demonstrated a better correlation between digital CLSM images and HE-stained sections.<sup>145-147</sup>

Direct stereomicroscopy with the so-called “rapid lump examination” (RLE) of unfixed and unfrozen surgical specimens enables microscopic assessment of tumour margins within a few minutes. Pilot studies showed a promising correlation of RLE and HE-stained paraffin sections as compared to frozen and paraffin sections of BCC.<sup>148-150</sup>

## 11. References

1. Ad Hoc Task F, Connolly SM, Baker DR, Coldiron BM, Fazio MJ, Storrs PA, et al. AAD/ACMS/ASDSA/ASMS 2012 appropriate use criteria for Mohs micrographic surgery: a report of the American Academy of Dermatology, American College of Mohs Surgery, American Society for Dermatologic Surgery Association, and the American Society for Mohs Surgery. *J Am Acad Dermatol*. 2012;67(4):531-50.
2. Ríos-Buceta L, Picoto A. Cirugía de Mohs. *Actas Dermo-Sifiliográficas*. 2003;94(8):503-23.
3. Hanke CW. Frederic Mohs Tribute. History of Mohs micrographic surgery. *Journal of drugs in dermatology : JDD*. 2002;1(2):169-74.
4. Mohs FE. Chemosurgery: A microscopically controlled method of cancer excision. *Archives of Surgery*. 1941;42(2):279-95.
5. Mohs F. Chemosurgery-Microscopically controlled surgery for skin cancer. Charles C Thomas Publisher, Springfield IL, USA; 1978.
6. Mohs F. Chemosurgery in cancer, gangrene and infections. Charles C Thomas Publisher, Springfield IL, USA; 1956.
7. Tromovitch TA, Stegeman SJ. Microscopically controlled excision of skin tumors: Chemosurgery (mohs): fresh tissue technique. *Archives of Dermatology*. 1974;110(2):231-2.
8. Zitelli JA. Wound healing by secondary intention. A cosmetic appraisal. *J Am Acad Dermatol*. 1983;9(3):407-15.
9. Nouri K, Patel AR, et al. "Mohs micrographic surgery." In: Nouri K. *Skin Cancer*. The McGraw-Hill Companies, Inc., China; 2008:482-490.
10. Karampoiki V, Flores FJ, Altinoz H, Chojnacka M, Karentzou I, Dambrosio M, et al. Screening Evaluation System--Europe (SESy\_Europe) met skin cancer screening. *Central European journal of public health*. 2007;15(2):71-3.
11. van Loo E, Mosterd K, Krekels GA, Roozeboom MH, Ostertag JU, Dirksen CD, et al. Surgical excision versus Mohs' micrographic surgery for basal cell carcinoma of the face: A randomised clinical trial with 10 year follow-up. *Eur J Cancer*. 2014;50(17):3011-20.
12. van der Geer S, Frunt M, Romero HL, Dellaert NP, Jansen-Vullers MH, Demeyere TB, et al. One-stop-shop treatment for basal cell carcinoma, part of a new disease management strategy. *J Eur Acad Dermatol Venereol*. 2012;26(9):1154-7.
13. Kimyai-Asadi A, Goldberg LH, Nemeth A, Friedman PM, Jih MH. Mohs micrographic surgery for elliptical excision of skin tumors: a surgical and histologic study. *Dermatol Surg*. 2004;30(10):1310-7; discussion 7-8.
14. Zabelinski M, Leithauser L, Godsey T, Gloster HM, Jr. Laboratory errors leading to nonmelanoma skin cancer recurrence after Mohs micrographic surgery. *Dermatol Surg*. 2015;41(8):913-6.
15. Tehrani H, May K, Morris A, Motley R. Does the dual use of toluidine blue and hematoxylin and eosin staining improve basal cell carcinoma detection by Mohs surgery trainees? *Dermatol Surg*. 2013;39(7):995-1000.
16. Loser CR, Rompel R, Mohrle M, Hafner HM, Kunte C, Hassel J, et al. S1 guideline: microscopically controlled surgery (MCS). *Journal der Deutschen Dermatologischen Gesellschaft = Journal of the German Society of Dermatology : JDDG*. 2015;13(9):942-51.
17. Boyer JD, Zitelli JA, Brodland DG, D'Angelo G. Local control of primary Merkel cell carcinoma: review of 45 cases treated with Mohs micrographic surgery with and without adjuvant radiation. *J Am Acad Dermatol*. 2002;47(6):885-92.
18. Boztepe G, Hohenleutner S, Landthaler M, Hohenleutner U. Munich method of micrographic surgery for basal cell carcinomas: 5-year recurrence rates with life-table analysis. *Acta Derm Venereol*. 2004;84(3):218-22.
19. Cohen LM, McCall MW, Zax RH. Mohs micrographic surgery for lentigo maligna and lentigo maligna melanoma. A follow-up study. *Dermatol Surg*. 1998;24(6):673-7.
20. Dinehart SM, Dodge R, Stanley WE, Franks HH, Pollack SV. Basal cell carcinoma treated with Mohs surgery. A comparison of 54 younger patients with 1050 older patients. *The Journal of dermatologic surgery and oncology*. 1992;18(7):560-6.
21. Gloster HM, Jr., Harris KR, Roenigk RK. A comparison between Mohs micrographic surgery and wide surgical excision for the treatment of dermatofibrosarcoma protuberans. *J Am Acad Dermatol*. 1996;35(1):82-7.
22. Hafner HM, Breuninger H, Moehrle M, Trilling B, Krimmel M. 3D histology-guided surgery for basal cell carcinoma and squamous cell carcinoma: recurrence rates and clinical outcome. *International journal of oral and maxillofacial surgery*. 2011;40(9):943-8.
23. Hafner HM, Moehrle M, Eder S, Trilling B, Rocken M, Breuninger H. 3D-Histological evaluation of surgery in dermatofibrosarcoma protuberans and malignant fibrous histiocytoma: differences in growth patterns and

- outcome. *European journal of surgical oncology : the journal of the European Society of Surgical Oncology and the British Association of Surgical Oncology*. 2008;34(6):680-6.
24. Hafner J, Schutz K, Morgenthaler W, Steiger E, Meyer V, Burg G. Micrographic surgery ('slow Mohs') in cutaneous sarcomas. *Dermatology (Basel, Switzerland)*. 1999;198(1):37-43.
  25. Leibovitch I, Huilgol SC, Selva D, Hill D, Richards S, Paver R. Cutaneous squamous cell carcinoma treated with Mohs micrographic surgery in Australia I. Experience over 10 years. *J Am Acad Dermatol*. 2005;53(2):253-60.
  26. Leibovitch I, Huilgol SC, Selva D, Hill D, Richards S, Paver R. Cutaneous squamous cell carcinoma treated with Mohs micrographic surgery in Australia II. Perineural invasion. *J Am Acad Dermatol*. 2005;53(2):261-6.
  27. Moehrle M, Dietz K, Garbe C, Breuninger H. Conventional histology vs. three-dimensional histology in lentigo maligna melanoma. *Br J Dermatol*. 2006;154(3):453-9.
  28. Thissen MR, Neumann MH, Schouten LJ. A systematic review of treatment modalities for primary basal cell carcinomas. *Arch Dermatol*. 1999;135(10):1177-83.
  29. Breuninger H, Adam P. 3D-histology evaluation in dermatologic surgery. Springer Medizinverlag, London, UK; 2013.
  30. Eberle FC, Kanyildiz M, Schnabl SM, Schulz C, Hafner HM, Adam P, et al. Three dimensional (3D) histology in daily routine: practical implementation and its evaluation. *Journal der Deutschen Dermatologischen Gesellschaft = Journal of the German Society of Dermatology : JDDG*. 2014;12(11):1028-35.
  31. Moehrle M, Breuninger H, Rocken M. A confusing world: what to call histology of three-dimensional tumour margins? *J Eur Acad Dermatol Venereol*. 2007;21(5):591-5.
  32. Garbe C, Dummer R, Kaufmann R, Tilgen W (ed.). *Dermatologische Onkologie*. Springer Medizinverlag, Heidelberg, Germany; 1997.
  33. Kopke LF, Konz B. [Micrographic surgery. A current methodological assessment]. *Der Hautarzt; Zeitschrift für Dermatologie, Venerologie, und verwandte Gebiete*. 1995;46(9):607-14.
  34. Breuninger H, Konz B, Burg Gn. Mikroskopisch kontrollierte Chirurgie bei malignen Hauttumoren. *Dtsch Arztebl International*. 2007;104(7):A-427.
  35. Drepper H. [Systematic histological control of the tumor bed as an advance in the operative removal of deep facial skin cancers]. *Der Hautarzt; Zeitschrift für Dermatologie, Venerologie, und verwandte Gebiete*. 1963;14:420-3.
  36. Sei JF, Chaussade V, Zimmermann U, Tchakerian A, Clerici T, Franc B, et al. [Mohs' micrographic surgery: history, principles, critical analysis of its efficacy and indications]. *Annales de dermatologie et de venerologie*. 2004;131(2):173-82.
  37. Breuninger H. Histologic control of excised tissue edges in the operative treatment of basal-cell carcinomas. *The Journal of dermatologic surgery and oncology*. 1984;10(9):724-8.
  38. Breuninger H, Schaumburg-Lever G. Control of excisional margins by conventional histopathological techniques in the treatment of skin tumours. An alternative to Mohs' technique. *The Journal of pathology*. 1988;154(2):167-71.
  39. Breuninger H, Holzschuh J. Die lückenlose histologische Darstellung der Schnittträger eines Hauttumorexizates (3-D-Histologie) in einer Schnittebene mittels der „Flundertechnik“. *Akt Dermatol* 1994;20:7–10.
  40. Moehrle M, Breuninger H, Taieb A, De Mascarel A, Vergier B. [3D histology: a micrographic surgical technique suitable for French dermatologists and pathologists in private and hospital practice]. *Annales de dermatologie et de venerologie*. 2007;134(1):87-93.
  41. Mohrle M, Breuninger H. [The Muffin technique--an alternative to Mohs' micrographic surgery]. *Journal der Deutschen Dermatologischen Gesellschaft = Journal of the German Society of Dermatology : JDDG*. 2006;4(12):1080-4.
  42. Johnson TM, Headington JT, Baker SR, Lowe L. Usefulness of the staged excision for lentigo maligna and lentigo maligna melanoma: the "square" procedure. *J Am Acad Dermatol*. 1997;37(5 Pt 1):758-64.
  43. Smeets NW, Krekels GA, Ostertag JU, Essers BA, Dirksen CD, Nieman FH, et al. Surgical excision vs Mohs' micrographic surgery for basal-cell carcinoma of the face: randomised controlled trial. *Lancet*. 2004;364(9447):1766-72.
  44. Mahoney MH, Joseph M, Temple CL. The perimeter technique for lentigo maligna: an alternative to Mohs micrographic surgery. *Journal of surgical oncology*. 2005;91(2):120-5.
  45. Burg G, Hirsch RD, Konz B, Braun-Falco O. Histographic surgery: accuracy of visual assessment of the margins of basal-cell epithelioma. *The Journal of dermatologic surgery*. 1975;1(3):21-4.
  46. Rigel DS, Robins P, Friedman RJ. Predicting recurrence of basal-cell carcinomas treated by microscopically controlled excision: a recurrence index score. *The Journal of dermatologic surgery and oncology*. 1981;7(10):807-10.



47. Boehringer A, Adam P, Schnabl S, Hafner HM, Breuninger H. Analysis of incomplete excisions of basal-cell carcinomas after breadloaf microscopy compared with 3D-microscopy: a prospective randomized and blinded study. *Journal of cutaneous pathology*. 2015;42(8):542-53.
48. Breuninger H, Schaumburg-Lever G, Holzschuh J, Horny HP. Desmoplastic squamous cell carcinoma of skin and vermilion surface: a highly malignant subtype of skin cancer. *Cancer*. 1997;79(5):915-9.
49. Guler-Nizam E, Leiter U, Metzler G, Breuninger H, Garbe C, Eigentler TK. Clinical course and prognostic factors of Merkel cell carcinoma of the skin. *Br J Dermatol*. 2009;161(1):90-4.
50. Boehringer A, Leiter U, Metzler G, Moehrle M, Garbe C, Breuninger H. Extramammary Paget's disease: extended subclinical growth detected using three-dimensional histology in routine paraffin procedure and course of the disease. *Dermatol Surg*. 2011;37(10):1417-26.
51. Zollo JD, Zeitouni NC. The Roswell Park Cancer Institute experience with extramammary Paget's disease. *Br J Dermatol*. 2000;142(1):59-65.
52. Breuninger H, Schlagenhauff B, Stroebel W, Schaumburg-Lever G, Rassner G. Patterns of local horizontal spread of melanomas: consequences for surgery and histopathologic investigation. *The American journal of surgical pathology*. 1999;23(12):1493-8.
53. Jahn V, Breuninger H, Garbe C, Maassen MM, Moehrle M. Melanoma of the nose: prognostic factors, three-dimensional histology, and surgical strategies. *The Laryngoscope*. 2006;116(7):1204-11.
54. Jahn V, Breuninger H, Garbe C, Moehrle M. Melanoma of the ear: prognostic factors and surgical strategies. *Br J Dermatol*. 2006;154(2):310-8.
55. Lichte V, Breuninger H, Metzler G, Haefner HM, Moehrle M. Acral lentiginous melanoma: conventional histology vs. three-dimensional histology. *Br J Dermatol*. 2009;160(3):591-9.
56. Mohrle M. [Micrographic controlled surgery (3D-histology) in cutaneous melanoma]. *Journal der Deutschen Dermatologischen Gesellschaft = Journal of the German Society of Dermatology : JDDG*. 2003;1(11):869-75.
57. Schulz C, Hafner HM, Breuninger H, Leiter U. [Local recurrence and survival in acral lentiginous melanoma comparing 3D histology and conventional histology]. *Journal der Deutschen Dermatologischen Gesellschaft = Journal of the German Society of Dermatology : JDDG*. 2014;12(10):881-90.
58. Smeets NW, Kuijpers DI, Nelemans P, Ostertag JU, Verhaegh ME, Krekels GA, et al. Mohs' micrographic surgery for treatment of basal cell carcinoma of the face--results of a retrospective study and review of the literature. *Br J Dermatol*. 2004;151(1):141-7.
59. Flohil SC, van Dorst AM, Nijsten T, Martino Neumann HA, Munte K. Mohs micrographic surgery for basal cell carcinomas: appropriateness of 'Rotterdam' criteria and predictive factors for three or more stages. *J Eur Acad Dermatol Venereol*. 2013;27(10):1228-35.
60. Paoli J, Daryoni S, Wennberg AM, Molne L, Gillstedt M, Miocic M, et al. 5-year recurrence rates of Mohs micrographic surgery for aggressive and recurrent facial basal cell carcinoma. *Acta Derm Venereol*. 2011;91(6):689-93.
61. Telfer NR, Colver GB, Morton CA, British Association of D. Guidelines for the management of basal cell carcinoma. *Br J Dermatol*. 2008;159(1):35-48.
62. Alam M, Berg D, Bhatia A, Cohen JL, Hale EK, Herman AR, et al. Association between number of stages in Mohs micrographic surgery and surgeon-, patient-, and tumor-specific features: a cross-sectional study of practice patterns of 20 early- and mid-career Mohs surgeons. *Dermatol Surg*. 2010;36(12):1915-20.
63. Cecchi R, Pavesi M, Bartoli L, Brunetti L, Rapicano V, Innocenti S. Micrographic surgery (fresh-tissue Tubingen technique) for treatment of basal cell carcinoma of the head: a single-centre report. *The Journal of dermatology*. 2008;35(10):678-9.
64. Rogers HW, Weinstock MA, Harris AR, Hinckley MR, Feldman SR, Fleischer AB, et al. Incidence estimate of nonmelanoma skin cancer in the United States, 2006. *Arch Dermatol*. 2010;146(3):283-7.
65. Brantsch KD, Meisner C, Schonfisch B, Trilling B, Wehner-Caroli J, Rocken M, et al. Analysis of risk factors determining prognosis of cutaneous squamous-cell carcinoma: a prospective study. *Lancet Oncol*. 2008;9(8):713-20.
66. Gonzalez JL, Cunningham K, Silverman R, Madan E, Nguyen BM. Comparison of the American Joint Committee on Cancer Seventh Edition and Brigham and Women's Hospital Cutaneous Squamous Cell Carcinoma Tumor Staging in Immunosuppressed Patients. *Dermatol Surg*. 2017;43(6):784-91.
67. Karia PS, Morgan FC, Califano JA, Schmultz CD. Comparison of Tumor Classifications for Cutaneous Squamous Cell Carcinoma of the Head and Neck in the 7th vs 8th Edition of the AJCC Cancer Staging Manual. *JAMA dermatology*. 2018;154(2):175-81.
68. Stratigos A, Garbe C, Lebbe C, Malvehy J, del Marmol V, Pehamberger H, et al. Diagnosis and treatment of invasive squamous cell carcinoma of the skin: European consensus-based interdisciplinary guideline. *Eur J Cancer*. 2015;51(14):1989-2007.

69. Kang SY, Toland AE. High risk cutaneous squamous cell carcinoma of the head and neck. *World journal of otorhinolaryngology - head and neck surgery*. 2016;2(2):136-40.
70. Lansbury L, Bath-Hextall F, Perkins W, Stanton W, Leonardi-Bee J. Interventions for non-metastatic squamous cell carcinoma of the skin: systematic review and pooled analysis of observational studies. *BMJ (Clinical research ed)*. 2013;347:f6153.
71. Breuninger H, Eigentler T, Bootz F, Hauschild A, Kortmann RD, Wolff K, et al. Brief S2k guidelines-- Cutaneous squamous cell carcinoma. *Journal der Deutschen Dermatologischen Gesellschaft = Journal of the German Society of Dermatology : JDDG*. 2013;11 Suppl 3:37-45, 39-47.
72. Chren MM, Linos E, Torres JS, Stuart SE, Parvataneni R, Boscardin WJ. Tumor recurrence 5 years after treatment of cutaneous basal cell carcinoma and squamous cell carcinoma. *The Journal of investigative dermatology*. 2013;133(5):1188-96.
73. Newlands C, Currie R, Memon A, Whitaker S, Woolford T. Non-melanoma skin cancer: United Kingdom National Multidisciplinary Guidelines. *The Journal of laryngology and otology*. 2016;130(S2):S125-s32.
74. Lane JE, Kent DE. Surgical margins in the treatment of nonmelanoma skin cancer and mohs micrographic surgery. *Current surgery*. 2005;62(5):518-26.
75. Cernea SS, Gontijo G, Pimentel ER, Tarle RG, Tassara G, Ferreira JA, et al. Indication guidelines for Mohs micrographic surgery in skin tumors. *Anais brasileiros de dermatologia*. 2016;91(5):621-7.
76. McLeod M, Choudhary S, Giannakakis G, Nouri K. Surgical treatments for lentigo maligna: a review. *Dermatol Surg*. 2011;37(9):1210-28.
77. Stevenson O, Ahmed I. Lentigo maligna : prognosis and treatment options. *American journal of clinical dermatology*. 2005;6(3):151-64.
78. Moehrle M, Metzger S, Schippert W, Garbe C, Rassner G, Breuninger H. "Functional" surgery in subungual melanoma. *Dermatol Surg*. 2003;29(4):366-74.
79. Mohrle M, Lichte V, Breuninger H. [Operative therapy of acral melanomas]. *Der Hautarzt; Zeitschrift fur Dermatologie, Venerologie, und verwandte Gebiete*. 2011;62(5):362-7.
80. Pflugfelder A, Kochs C, Blum A, Capellaro M, Czeschik C, Dettenborn T, et al. Malignant melanoma S3-guideline "diagnosis, therapy and follow-up of melanoma". *Journal der Deutschen Dermatologischen Gesellschaft = Journal of the German Society of Dermatology : JDDG*. 2013;11 Suppl 6:1-116, 1-26.
81. Bae JM, Choi YY, Kim H, Oh BH, Roh MR, Nam K, et al. Mohs micrographic surgery for extramammary Paget disease: a pooled analysis of individual patient data. *J Am Acad Dermatol*. 2013;68(4):632-7.
82. Tolkachjov SN. Adnexal Carcinomas Treated With Mohs Micrographic Surgery: A Comprehensive Review. *Dermatol Surg*. 2017;43(10):1199-207.
83. Kamalpour L, Brindise RT, Nodzenski M, Bach DQ, Veledar E, Alam M. Primary cutaneous mucinous carcinoma: a systematic review and meta-analysis of outcomes after surgery. *JAMA dermatology*. 2014;150(4):380-4.
84. Palamaras I, McKenna JD, Robson A, Barlow RJ. Microcystic adnexal carcinoma: a case series treated with mohs micrographic surgery and identification of patients in whom paraffin sections may be preferable. *Dermatol Surg*. 2010;36(4):446-52.
85. Belin E, Ezzedine K, Stanislas S, Lalanne N, Beylot-Barry M, Taieb A, et al. Factors in the surgical management of primary eccrine porocarcinoma: prognostic histological factors can guide the surgical procedure. *Br J Dermatol*. 2011;165(5):985-9.
86. Song SS, Wu Lee W, Hamman MS, Jiang SI. Mohs micrographic surgery for eccrine porocarcinoma: an update and review of the literature. *Dermatol Surg*. 2015;41(3):301-6.
87. Vleugels FR, Girouard SD, Schmults CD, Ng AK, Russell SE, Wang LC, et al. Metastatic eccrine porocarcinoma after Mohs micrographic surgery: a case report. *Journal of clinical oncology : official journal of the American Society of Clinical Oncology*. 2012;30(21):e188-91.
88. Tidwell WJ, Mayer JE, Malone J, Schadt C, Brown T. Treatment of eccrine porocarcinoma with Mohs micrographic surgery: a cases series and literature review. *International journal of dermatology*. 2015;54(9):1078-83.
89. Tolkachjov SN, Hocker TL, Camilleri MJ, Baum CL. Treatment of Porocarcinoma With Mohs Micrographic Surgery: The Mayo Clinic Experience. *Dermatol Surg*. 2016;42(6):745-50.
90. Xu YG, Hinshaw M, Longley BJ, Ilyas H, Snow SN. Cutaneous adenoid cystic carcinoma with perineural invasion treated by mohs micrographic surgery-a case report with literature review. *Journal of oncology*. 2010;2010:469049.
91. Matin RN, Acland KM, Williams HC. Is Mohs micrographic surgery more effective than wide local excision for treatment of dermatofibrosarcoma protuberans in reducing risk of local recurrence? A Critically Appraised Topic. *Br J Dermatol*. 2012;167(1):6-9.
92. Foroozan M, Sei JF, Amini M, Beauchet A, Saiag P. Efficacy of Mohs micrographic surgery for the treatment of dermatofibrosarcoma protuberans: systematic review. *Arch Dermatol*. 2012;148(9):1055-63.



93. Lee SH, Oh Y, Nam KA, Oh B, Roh MR, Chung KY. Mohs micrographic surgery for dermatofibrosarcoma protuberans: comparison of frozen and paraffin techniques. *J Eur Acad Dermatol Venereol.* 2018;32(12):2171-7.
94. Tarantola TI, Vallow LA, Halyard MY, Weenig RH, Warschaw KE, Grotz TE, et al. Prognostic factors in Merkel cell carcinoma: analysis of 240 cases. *J Am Acad Dermatol.* 2013;68(3):425-32.
95. Kline L, Coldiron B. Mohs Micrographic Surgery for the Treatment of Merkel Cell Carcinoma. *Dermatol Surg.* 2016;42(8):945-51.
96. O'Connor WJ, Roenigk RK, Brodland DG. Merkel cell carcinoma. Comparison of Mohs micrographic surgery and wide excision in eighty-six patients. *Dermatol Surg.* 1997;23(10):929-33.
97. Cowan N, Goldenberg A, Basu P, Eilers R, Hau J, S IBJ. A Retrospective Analysis of Complication Rates in Mohs Micrographic Surgery Patients With Clinically Large Tumors and Tumors With Aggressive Subclinical Extension. *Journal of drugs in dermatology : JDD.* 2018;17(5):511-5.
98. Moehrle M, Breuninger H, Schippert W, Hafner HM. Letter: Imiquimod 5% cream as adjunctive therapy for primary, solitary, nodular basal cell carcinomas before Mohs micrographic surgery: a randomized, double-blind, vehicle-controlled study. *Dermatol Surg.* 2010;36(3):428-30.
99. Sexton M, Jones DB, Maloney ME. Histologic pattern analysis of basal cell carcinoma. Study of a series of 1039 consecutive neoplasms. *J Am Acad Dermatol.* 1990;23(6 Pt 1):1118-26.
100. Stiegel E, Lam C, Schowalter M, Somani AK, Lucas J, Poblete-Lopez C. Correlation Between Original Biopsy Pathology and Mohs Intraoperative Pathology. *Dermatol Surg.* 2018;44(2):193-7.
101. Morton CA, Szeimies RM, Sidoroff A, Braathen LR. European guidelines for topical photodynamic therapy part 1: treatment delivery and current indications - actinic keratoses, Bowen's disease, basal cell carcinoma. *J Eur Acad Dermatol Venereol.* 2013;27(5):536-44.
102. Al-Niaini F, Sheth N, Kurwa HA, Mallipeddi R. Photodynamic Therapy Followed by Mohs Micrographic Surgery Compared to Mohs Micrographic Surgery Alone for the Treatment of Basal Cell Carcinoma: Results of a Pilot Single-Blinded Randomised Controlled Trial. *Journal of cutaneous and aesthetic surgery.* 2015;8(2):88-91.
103. Kuijpers DI, Smeets NW, Krekels GA, Thissen MR. Photodynamic therapy as adjuvant treatment of extensive basal cell carcinoma treated with Mohs micrographic surgery. *Dermatol Surg.* 2004;30(5):794-8.
104. Stary G, Bangert C, Tauber M, Strohal R, Kopp T, Stingl G. Tumoricidal activity of TLR7/8-activated inflammatory dendritic cells. *The Journal of experimental medicine.* 2007;204(6):1441-51.
105. Bostanci S, Kocyigit P, Vural S, Heper AO, Botsali A. Long-Term Follow-Up Results of Topical Imiquimod Treatment in Basal Cell Carcinoma. *Dermatol Surg.* 2018;44(1):36-41.
106. Roozeboom MH, Arits AH, Mosterd K, Sommer A, Essers BA, de Rooij MJ, et al. Three-Year Follow-Up Results of Photodynamic Therapy vs. Imiquimod vs. Fluorouracil for Treatment of Superficial Basal Cell Carcinoma: A Single-Blind, Noninferiority, Randomized Controlled Trial. *The Journal of investigative dermatology.* 2016;136(8):1568-74.
107. van der Geer S, Martens J, van Roij J, Brand E, Ostertag JU, Verhaegh ME, et al. Imiquimod 5% cream as pretreatment of Mohs micrographic surgery for nodular basal cell carcinoma in the face: a prospective randomized controlled study. *Br J Dermatol.* 2012;167(1):110-5.
108. Sukal SA, Mahlberg MJ, Brightman L, Daniel DR, Mintzis MM, Geronemus RG. What lies beneath? A lesson for the clinician. Intraoperative frozen section appearance of persistent basal cell carcinoma after apparent cure with imiquimod 5% cream. *Dermatol Surg.* 2009;35(11):1831-4.
109. Thissen MR, Kuijpers DI, Krekels GA. Local immune modulator (imiquimod 5% cream) as adjuvant treatment after incomplete Mohs micrographic surgery for large, mixed type basal cell carcinoma: a report of 3 cases. *Journal of drugs in dermatology : JDD.* 2006;5(5):461-4.
110. Siller G, Rosen R, Freeman M, Welburn P, Katsamas J, Ogbourne SM. PEP005 (ingenol mebutate) gel for the topical treatment of superficial basal cell carcinoma: results of a randomized phase IIa trial. *The Australasian journal of dermatology.* 2010;51(2):99-105.
111. Stieger M, Hunger RE. Ingenol Mebutate Treatment in a Patient with Gorlin Syndrome. *Dermatology (Basel, Switzerland).* 2016;232 Suppl 1:29-31.
112. Migden MR, Chang ALS, Dirix L, Stratigos AJ, Lear JT. Emerging trends in the treatment of advanced basal cell carcinoma. *Cancer treatment reviews.* 2018;64:1-10.
113. Trakatelli M, Morton C, Nagore E, Ulrich C, Del Marmol V, Peris K, et al. Update of the European guidelines for basal cell carcinoma management. *European journal of dermatology : EJD.* 2014;24(3):312-29.
114. Cheraghi N, Cognetta A, Goldberg D. Radiation Therapy in Dermatology: Non-Melanoma Skin Cancer. *Journal of drugs in dermatology : JDD.* 2017;16(5):464-9.
115. Jackson JE, Dickie GJ, Wiltshire KL, Keller J, Tripcony L, Poulsen MG, et al. Radiotherapy for perineural invasion in cutaneous head and neck carcinomas: toward a risk-adapted treatment approach. *Head & neck.* 2009;31(5):604-10.

116. National Comprehensive Cancer Network. NCCN clinical practice guidelines in oncology: basal cell skin cancer (Version 1.2019). 2018. Available at: [www.nccn.org](http://www.nccn.org) Accessed: September 10, 2018. .
117. Sekulic A, Migden MR, Lewis K, Hainsworth JD, Solomon JA, Yoo S, et al. Pivotal ERIVANCE basal cell carcinoma (BCC) study: 12-month update of efficacy and safety of vismodegib in advanced BCC. *J Am Acad Dermatol*. 2015;72(6):1021-6.e8.
118. Ally MS, Aasi S, Wysong A, Teng C, Anderson E, Bailey-Healy I, et al. An investigator-initiated open-label clinical trial of vismodegib as a neoadjuvant to surgery for high-risk basal cell carcinoma. *J Am Acad Dermatol*. 2014;71(5):904-11.e1.
119. Kwon GP, Ally MS, Bailey-Healy I, Oro AE, Kim J, Chang AL, et al. Update to an open-label clinical trial of vismodegib as neoadjuvant before surgery for high-risk basal cell carcinoma (BCC). *J Am Acad Dermatol*. 2016;75(1):213-5.
120. Chang AL, Atwood SX, Tartar DM, Oro AE. Surgical excision after neoadjuvant therapy with vismodegib for a locally advanced basal cell carcinoma and resistant basal carcinomas in Gorlin syndrome. *JAMA dermatology*. 2013;149(5):639-41.
121. Migden MR, Guminski A, Gutzmer R, Dirix L, Lewis KD, Combemale P, et al. Treatment with two different doses of sonidegib in patients with locally advanced or metastatic basal cell carcinoma (BOLT): a multicentre, randomised, double-blind phase 2 trial. *Lancet Oncol*. 2015;16(6):716-28.
122. Casey D, Demko S, Shord S, Zhao H, Chen H, He K, et al. FDA Approval Summary: Sonidegib for Locally Advanced Basal Cell Carcinoma. *Clinical cancer research : an official journal of the American Association for Cancer Research*. 2017;23(10):2377-81.
123. Morinello E, Pignatello M, Villabruna L, Goelzer P, Burgin H. Embryofetal development study of vismodegib, a hedgehog pathway inhibitor, in rats. *Birth defects research Part B, Developmental and reproductive toxicology*. 2014;101(2):135-43.
124. Brechbiel J, Miller-Moslin K, Adjei AA. Crosstalk between hedgehog and other signaling pathways as a basis for combination therapies in cancer. *Cancer treatment reviews*. 2014;40(6):750-9.
125. Ballantyne AJ. Perineural invasion by SCC. *The Journal of dermatologic surgery and oncology*. 1984;10(7):502-4.
126. Han A, Ratner D. What is the role of adjuvant radiotherapy in the treatment of cutaneous squamous cell carcinoma with perineural invasion? *Cancer*. 2007;109(6):1053-9.
127. Salido-Vallejo R, Cuevas-Asencio I, Garnacho-Sucedo G, Gonzalez-Menchen A, Alcantara-Reifs C, De la Corte-Sanchez S, et al. Neoadjuvant intralesional methotrexate in cutaneous squamous cell carcinoma: a comparative cohort study. *J Eur Acad Dermatol Venereol*. 2016;30(7):1120-4.
128. Lee EH, Klassen AF, Lawson JL, Cano SJ, Scott AM, Pusic AL. Patient experiences and outcomes following facial skin cancer surgery: A qualitative study. *The Australasian journal of dermatology*. 2016;57(3):e100-4.
129. Rhee JS, Matthews BA, Neuburg M, Smith TL, Burzynski M, Nattinger AB. Skin cancer and quality of life: assessment with the Dermatology Life Quality Index. *Dermatol Surg*. 2004;30(4 Pt 1):525-9.
130. Tokede O, Jadotte YT, Nkemjika S, Holly C, Cohen P, Schwartz R, et al. Effectiveness of Mohs micrographic surgery for nonmelanoma skin cancer: a systematic review protocol. *JBI database of systematic reviews and implementation reports*. 2017;15(3):666-75.
131. Hussain W, Affleck A, Al-Niaimi F, Cooper A, Craythorne E, Fleming C, et al. Safety, complications and patients' acceptance of Mohs micrographic surgery under local anaesthesia: results from the U.K. MAPS (Mohs Acceptance and Patient Safety) Collaboration Group. *Br J Dermatol*. 2017;176(3):806-8.
132. Asgari MM, Bertenthal D, Sen S, Sahay A, Chren MM. Patient satisfaction after treatment of nonmelanoma skin cancer. *Dermatol Surg*. 2009;35(7):1041-9.
133. Chren MM, Sahay AP, Bertenthal DS, Sen S, Landefeld CS. Quality-of-life outcomes of treatments for cutaneous basal cell carcinoma and squamous cell carcinoma. *The Journal of investigative dermatology*. 2007;127(6):1351-7.
134. Asgari MM, Warton EM, Neugebauer R, Chren MM. Predictors of patient satisfaction with Mohs surgery: analysis of preoperative, intraoperative, and postoperative factors in a prospective cohort. *Arch Dermatol*. 2011;147(12):1387-94.
135. Eom CS, Shin DW, Kim SY, Yang HK, Jo HS, Kweon SS, et al. Impact of perceived social support on the mental health and health-related quality of life in cancer patients: results from a nationwide, multicenter survey in South Korea. *Psycho-oncology*. 2013;22(6):1283-90.
136. Renzi C, Abeni D, Picardi A, Agostini E, Melchi CF, Pasquini P, et al. Factors associated with patient satisfaction with care among dermatological outpatients. *Br J Dermatol*. 2001;145(4):617-23.
137. Renzi C, Tabolli S, Picardi A, Abeni D, Puddu P, Braga M. Effects of patient satisfaction with care on health-related quality of life: a prospective study. *J Eur Acad Dermatol Venereol*. 2005;19(6):712-8.

138. Ali FR, Al-Niaimi F, Craythorne EE, Patalay R, Mallipeddi R. Patient satisfaction and the waiting room in Mohs surgery: appropriate prewarning may abrogate boredom. *J Eur Acad Dermatol Venereol.* 2017;31(7):e337-e8.
139. Eberle FC, Schippert W, Trilling B, Rocken M, Breuninger H. Cosmetic results of histographically controlled excision of non-melanoma skin cancer in the head and neck region. *Journal der Deutschen Dermatologischen Gesellschaft = Journal of the German Society of Dermatology : JDDG.* 2005;3(2):109-12.
140. Hafiji J, Salmon P, Hussain W. Patient satisfaction with post-operative telephone calls after Mohs micrographic surgery: a New Zealand and U.K. experience. *Br J Dermatol.* 2012;167(3):570-4.
141. Viola KV, Jhaveri MB, Soulos PR, Turner RB, Tolpinrud WL, Doshi D, et al. Mohs micrographic surgery and surgical excision for nonmelanoma skin cancer treatment in the Medicare population. *Arch Dermatol.* 2012;148(4):473-7.
142. Kaeb S, Landthaler M, Hohenleutner U. Confocal laser scanning microscopy--evaluation of native tissue sections in micrographic surgery. *Lasers in medical science.* 2009;24(5):819-23.
143. Schule D, Breuninger H, Schippert W, Dietz K, Moehrle M. Confocal laser scanning microscopy in micrographic surgery (three-dimensional histology) of basal cell carcinomas. *Br J Dermatol.* 2009;161(3):698-700.
144. Ziefle S, Schule D, Breuninger H, Schippert W, Moehrle M. Confocal laser scanning microscopy vs 3-dimensional histologic imaging in basal cell carcinoma. *Arch Dermatol.* 2010;146(8):843-7.
145. Bennisar A, Vilata A, Puig S, Malvey J. Ex vivo fluorescence confocal microscopy for fast evaluation of tumour margins during Mohs surgery. *Br J Dermatol.* 2014;170(2):360-5.
146. Longo C, Rajadhyaksha M, Ragazzi M, Nehal K, Gardini S, Moscarella E, et al. Evaluating ex vivo fluorescence confocal microscopy images of basal cell carcinomas in Mohs excised tissue. *Br J Dermatol.* 2014;171(3):561-70.
147. Peters N, Schubert M, Metzler G, Geppert JP, Moehrle M. Diagnostic accuracy of a new ex vivo confocal laser scanning microscope compared to H&E-stained paraffin slides for micrographic surgery of basal cell carcinoma. *J Eur Acad Dermatol Venereol.* 2019;33(2):298-304.
148. Moehrle M, Kaflein L, Ziefle S, Metzler G. Rapid lump examination (RLE) - a new tool for Mohs surgery? *Journal der Deutschen Dermatologischen Gesellschaft = Journal of the German Society of Dermatology : JDDG.* 2011;9(7):534-8.
149. Peters N, Schubert M, Geppert JP, Moehrle M. Micrographic controlled surgery of basal cell carcinomas - Rapid Lump Examination (RLE) in comparison to H&E-stained paraffin sections. *Br J Dermatol.* 2019.
150. Veenstra M, Ostertag J, Verhaegh M, Nuessle N, Moehrle M. Rapid Lump Examination as a New Aid to Speedup Mohs Micrographic Surgery: A Pilot Study. *Dermatol Surg.* 2016;42(5):665-71.

## 12. Appendix - H&E staining procedure.

### The following steps are required for H&E staining:

- Fixation: Fix the slide for a few seconds in a 70% alcohol solution. This will remove the OCT compound and allows for fixation of the tissue.
- Rinsing: Rinse the fixative off of the slides by gently running tap water over them and dry the slides for a few seconds.
- Haematoxylin: Place the slides in the haematoxylin staining solution and shake the slides gently, ensuring even staining.
- Rinsing: Rinse the slides in running tap water at room temperature or warmer so the excess of staining solution washes away and helps enhance the staining characteristics of Haematoxylin.
- Alcohol rinse: Rinse the slides in 95% alcohol solution to prepare the tissue for the next step in the staining process.
- Eosin: Place the slides for a few seconds in the eosin staining solution and shake the slides gently to ensure even staining.
- Alcohol run: Dip the slides in an alcohol run of 95% solution, followed by 100% and 100% to dilute and remove the excess of Eosin from the slides.
- Xylene: Place the slides in xylene solution, a clearing solution, that will clear the stained tissue and prepared it to be covered by mounting medium and coverslips.
- Mounting and coverslip: Apply mounting medium, a clear liquid that turns into an adhesive as it dries, on top of the tissue in order to adhere the coverslip to the slide. The mounting medium and the coverslip covering the tissue on the slide will guarantee that the tissue can be stored for many years.

The LT can stain the slides by hand or by using an automatic linear staining machine. Common protocols used to stain the slide(s) include:

<b>Step</b>	<b>By Hand</b>	<b>Staining machine (30 s for each step)</b>
Alcohol 70%	30 s	Alcohol 70%
Drying / wash water	30 s	Drying
Haematoxylin	90 s	Haematoxylin
Tap water (running)	30 s	Tap water (running)
Tap water (running)	30 s	Tap water (running)
Tap water (running)	30 s	Tap water (running)
Alcohol 95%	30 s	Alcohol 95%
Eosin	5 s	Eosin
Alcohol 95%	Short dips	Alcohol 95%
Alcohol 100%	Short dips	Alcohol 100%
Alcohol 100%	Short dips	Alcohol 100%
Xylene	30 s	Xylene
Mount and coverslip	Mount and coverslip	Mount and coverslip